

Diagnosis and Management of Pediatric Autoimmune Liver Disease: ESPGHAN Hepatology Committee Position Statement

*Giorgina Mieli-Vergani, *Diego Vergani, †Ulrich Baumann, ‡Piotr Czubkowski, §Dominique Debray, ||Antal Dezsofi, ¶Björn Fischler, #Girish Gupte, **Loreto Hierro, ††Giuseppe Indolfi, ‡‡Jörg Jahnel, §§Françoise Smets, ||||Henkjan J. Verkade, and *Nedim Hadžić

ABSTRACT

Paediatric autoimmune liver disease is characterized by inflammatory liver histology, circulating autoantibodies, and increased levels of IgG, in the absence of a known etiology. Three conditions have a likely autoimmune pathogenesis: autoimmune hepatitis (AIH), autoimmune sclerosing cholangitis, and de novo AIH after liver transplantation. Two types of pediatric AIH are recognized according to seropositivity for smooth muscle and/or antinuclear antibody (AIH-1) or liver kidney microsomal type 1 and/or anti-liver cytosol type 1 antibodies (AIH-2). Pertinent issues addressing the diagnosis, treatment, and long-term follow-up were formulated by a core group of ESPGHAN members. They have commissioned the first authors with execution of this project. Initially, they have performed a systematic literature search on MEDLINE, ResearchGate, and Mendeley databases during the last 30 years and produced a document focusing on prospective and retrospective studies in children. The ESPGHAN core group and ESPGHAN Hepatology Committee members voted on each recommendation, using a formal voting technique.

Received July 23, 2017; accepted October 10, 2017.

From the *MowatLabs, Paediatric Liver, GI & Nutrition Centre, King's College Hospital, London, UK, the †Pädiatrische Gastroenterologie und Hepatologie, Medizinische Hochschule, Hannover, Germany, the ‡Department of Gastroenterology, Hepatology, Nutrition Disturbances and Pediatrics, The Children's Memorial Health Institute, Warsaw, Poland, the §Pediatric Hepatology Unit, AP-HP-Hôpital Necker Enfants Malades, Paris, France, the ||First Department of Paediatrics, Semmelweis University, Budapest, Hungary, the ¶Department of Pediatrics, Karolinska University Hospital, CLINTEC, Karolinska Institutet, Stockholm, Sweden, the #Liver Unit (Including Small Bowel Transplantation), Department of Gastroenterology and Nutrition, Birmingham Children's Hospital, Birmingham, UK, the **Hospital Infantil Universitario La Paz, Madrid, Spain, the ††Paediatric and Liver Unit, Meyer Children's University Hospital of Florence, Firenze, Italy, the ‡‡Division of General Pediatrics, Department of Pediatrics and Adolescent Medicine, Medical University of Graz, Graz, Austria, the §§UCL, Cliniques Universitaires Saint-Luc, Pediatric Gastroenterology and Hepatology, Brussels, Belgium, and the ||||Dept of Pediatrics, Center for Liver, Digestive, and Metabolic Diseases, University Medical Center Groningen, Groningen, the Netherlands.

Address correspondence and reprint requests to Giorgina Mieli-Vergani, Professor of Paediatric Hepatology, Pediatric Liver, GI & Nutrition Centre, King's College Hospital, Denmark Hill, London SE5 9RS, UK (e-mail: giorgina.vergani@kcl.ac.uk).

G.M-V. and D.V. contributed equally, and are joint first authors.

The authors report no conflicts of interest.

Copyright © 2017 by European Society for Pediatric Gastroenterology, Hepatology, and Nutrition and North American Society for Pediatric Gastroenterology, Hepatology, and Nutrition

DOI: 10.1097/MPG.0000000000001801

Key Words: autoimmune hepatitis, autoimmune liver disease, autoimmune sclerosing cholangitis, children, pediatric

(JPGN 2018;66: 345–360)

What Is Known

- Juvenile autoimmune hepatitis is divided in type 1 (smooth muscle and/or antinuclear antibody-positive) and type 2 (liver kidney microsomal type 1 and/or anti-liver cytosol type 1 antibody-positive).
- Autoimmune hepatitis is more aggressive in childhood than in adulthood.
- Scoring systems for autoimmune hepatitis diagnosis in adults are not applicable to pediatric patients.

What Is New

- Pediatric autoimmune liver diseases are diagnosed more frequently than in the past, because of enhanced awareness, real increase in their prevalence, and/or decrease in viral hepatitis-related disease.
- Juvenile sclerosing cholangitis often has autoimmune features identical to autoimmune hepatitis type 1, diagnosis being possible only with cholangiography.
- A scoring system for the diagnosis of autoimmune liver disease in pediatric age is proposed for testing and validation.

In children and adolescents, there are 3 liver disorders in which liver damage is likely to arise from an autoimmune attack: autoimmune hepatitis (AIH), autoimmune sclerosing cholangitis (ASC), and de novo AIH after liver transplant. These conditions can present insidiously or with a picture of acute hepatitis. They usually respond to immunosuppressive treatment, which should be instituted as soon as a diagnosis is made to avoid disease progression.

Hitherto considered rare, pediatric autoimmune liver diseases are being diagnosed more frequently than in the past because of enhanced awareness, a real increase in their prevalence, and/or the decrease in viral hepatitis-related disease, following the advents of successful vaccination for hepatitis B and effective treatment for hepatitis C. The increased interest in pediatric autoimmune liver

KEY POINTS

- Three forms of pediatric liver disease recognize an autoimmune component to their pathogenesis: AIH, ASC, and de novo AIH after liver transplant (LT).
- According to serology, autoimmune hepatitis is further divided into 2 subtypes: type 1, positive for ANA and/or SMA, and type 2, positive for anti-LKM-1 and/or anti-LC-1 autoantibodies.
- ASC is serologically (ANA/SMA) and histologically similar to autoimmune hepatitis type 1, but in addition has bile duct damage demonstrable by cholangiography, often already at presentation. Positivity for peripheral anti-nuclear neutrophil antibodies is more frequent in ASC than AIH. Rare patients with ASC are anti-LKM-1-positive.
- De novo AIH after LT is characterized by autoantibody seropositivity (ANA, SMA, and typical or atypical anti-LKM-1).
- The characteristic histological feature, common to AIH, ASC, and de novo AIH after transplantation, is interface hepatitis.
- Parenchymal inflammation responds satisfactorily to standard immunosuppressive treatment with steroids \pm azathioprine both in AIH and ASC, but in ASC, the bile duct disease progresses in about 50% of cases, leading to end-stage liver disease requiring transplantation more frequently than in AIH.
- ASC is more frequently associated to IBD than AIH. Deterioration of liver disease, as well as the risk of disease recurrence after transplant, is correlated to the activity of the intestinal disease.
- The minority of patients who do not respond to standard treatment, and those who relapse frequently, should be offered alternative immunosuppression, the efficacy of which is still anecdotal (including in order of priority MMF, calcineurin inhibitors, rituximab, anti-TNF- α).
- Relapse affects approximately 40% of patients while on treatment and is frequently due to non-adherence, particularly in adolescents.
- It is prudent to treat children for at least 2 to 3 years before attempting treatment withdrawal, which should be considered only if transaminase and IgG levels have been normal and autoantibody negative or low titer (1:20 by immunofluorescence) for at least a year. Before withdrawal, liver biopsy should be repeated to exclude residual inflammatory changes.
- Both AIH and ASC can recur after LT, recurrence being more common in ASC than in AIH.
- De novo AIH after LT for non-autoimmune conditions responds to the classical treatment of AIH, but not to standard antirejection treatment.

disease is reflected by the large number of recent reviews covering this topic (1–17).

In 2017, the ESPGHAN Hepatology Committee commissioned G.M.-V. and D.V. to prepare a position paper to be reviewed and approved by all 12 committee members, representing the European pediatric hepatologist community. The aim of this position paper is to outline diagnostic and management issues

specifically related to juvenile autoimmune liver disease to provide guidance for complicated clinical scenarios, on the bases of the evidence available in the literature.

For the purpose of this position paper, key publications on autoimmune liver disease in children published during the last 30 years as well as English-language abstracts from January 2007 to April 2017 cited in PubMed (www.ncbi.nlm.nih.gov/pubmed) were selected using the search words “autoimmune hepatitis,” “childhood/juvenile autoimmune liver disease,” “primary sclerosing cholangitis,” “autoimmune sclerosing cholangitis,” “liver transplantation,” and “recurrent liver disease”). Complementary searches using the same words were made in ResearchGate (www.researchgate.net) and Mendeley (www.mendeley.com). Fundamental characteristics of the abstracts judged pertinent to the review were noted, and full-length articles/reviews were selected from the abstracts. Citations were chosen on the basis of their relevance to the text.

The first draft of the position paper was sent to 12 ESPGHAN Hepatology Committee members for review and comments. Then, the members voted on each statement, using the nominal voting technique (see Position Statements below).

AUTOIMMUNE HEPATITIS

AIH is the prototype autoimmune liver disease both in adults and children, having been the first to be described in the 1950s (18–20). It is a progressive inflammatory hepatopathy, which, if untreated, evolves to end-stage liver disease. The most typical features of AIH are female preponderance, hypergammaglobulinemia/increased immunoglobulin G (IgG), seropositivity for circulating autoantibodies, and a picture of interface hepatitis on histology. AIH responds to immunosuppressive treatment in the majority of cases. Treatment should be instituted promptly upon diagnosis. If left untreated, AIH usually progresses to liver failure requiring transplantation. Two types of AIH are distinguished according to serological profile: type 1 AIH (AIH-1) is positive for antinuclear antibody (ANA) and/or anti-smooth muscle antibody (SMA), and type 2 AIH (AIH-2) is defined by positivity for anti-liver kidney microsomal type 1 antibody (anti-LKM-1) and/or for anti-liver cytosol type 1 antibody (anti-LC-1).

Diagnostic Criteria

The diagnosis of AIH is based on a combination of clinical, biochemical, immunological, and histological features and the exclusion of other known causes of liver disease that may share serological and histological features with AIH (eg, hepatitis B, C, and E, Wilson disease, nonalcoholic steatohepatitis, and drug-induced liver disease). Liver biopsy is needed to confirm the diagnosis and to evaluate the severity of liver damage (21,22). In the absence of a single diagnostic test for AIH, the International Autoimmune Hepatitis Group (IAIHG) has devised a diagnostic system for comparative and research purposes, which includes several positive and negative scores, the sum of which gives a value indicative of probable or definite AIH (23,24). A simplified IAIHG scoring system published more recently is better suited to clinical application (25). Neither scoring system is, however, suitable to the juvenile form of the disease (26), in particular in the context of fulminant hepatic failure (FHF) (27,28). Moreover, diagnostically relevant autoantibodies in pediatrics often have titers lower than the cutoff value considered positive in adults (29) and neither IAIHG system allows distinction between AIH and ASC (see below) (30,31), which can only be differentiated if a cholangiogram is performed at presentation.

Pathologic Features

The typical histological feature of AIH is interface hepatitis, which is however not exclusive to this condition (32). Interface hepatitis is characterized by a dense inflammatory infiltrate composed of lymphocytes and plasma cells, which crosses the limiting plate and invades the surrounding parenchyma. Hepatocytes surrounded by inflammatory cells become swollen and undergo pyknotic necrosis. Though plasma cells are characteristically abundant at the interface and within the lobule, their presence in low number does not exclude the diagnosis of AIH. When AIH presents acutely, and during episodes of relapse, a common histological finding is panlobular hepatitis with bridging necrosis. Other non-specific features that may point to the diagnosis of AIH are emperipolesis and hepatocyte rosetting (33), which in a recent study have been suggested to be stronger indicators of AIH than interface hepatitis or plasma-cell rich infiltrate (34). These findings, however, are not present in all patients. In a pediatric cohort, wherein the histology of patients with autoimmune liver disease was compared with that of patients with nonautoimmune liver disease, the typical histology comprising interface hepatitis, portal lymphoplasmacytic infiltrate, rosette formation, and emperipolesis, was observed in 56% of patients with autoimmune liver disease. Emperipolesis and in particular rosette formation were significantly associated with an autoimmune diagnosis (35). A recent article in a pediatric AIH cohort suggests that the finding of hyaline droplets in Kupffer cells is a useful diagnostic marker to distinguish AIH from other forms of chronic hepatitis. The hyaline droplets occur specifically in AIH regardless of the type and are positive for IgG by immunohistochemical analysis, correlating with a >2-fold increase in serum level of IgG (36).

Histology is also the criterion standard for evaluating the extent of fibrosis and helps in identifying overlap syndromes as well as the possible presence of concomitant diseases, such as nonalcoholic fatty liver disease (37). Although inflammatory changes surrounding the bile ducts are present also in a small proportion of patients with classical AIH, when conspicuous, they suggest an overlap with sclerosing cholangitis (31).

In contrast to patients with an insidious course, those presenting with acute liver failure (ALF) show histological damage predominantly in the centrilobular area (38) often with massive necrosis and multilobular collapse indistinguishable from other forms of ALF (39). In one study on pediatric patients presenting with ALF, histology did not allow distinguishing autoimmune ALF from indeterminate ALF (40). In the presence of coagulopathy, liver biopsy should be performed by the transjugular route, which is not without risk. If transjugular biopsy is technically not available, the absence of histology should not preclude prompt initiation of immunosuppressive treatment, but liver biopsy should be performed as soon as coagulation indices permit.

Autoantibodies

Key to the diagnosis of AIH is positivity for circulating autoantibodies (23–25,29), although autoantibodies can be present in other liver disorders and are not diagnostic in isolation. Their detection by indirect immunofluorescence on a rodent substrate not only assists in the diagnosis but also allows differentiation into the 2 forms of AIH: ANA and SMA characterize AIH-1; anti-LKM1 and anti-LC-1 define AIH-2 (29,41). The 2 autoantibody profiles can occur simultaneously, but not frequently. As interpretation of the immunofluorescence patterns can be difficult, guidelines have been provided by the IAIHG regarding methodology and interpretation of liver autoimmune serology (29). A major advantage of testing for autoantibodies by indirect immunofluorescence on a freshly

prepared rodent substrate that includes kidney, liver, and stomach is that it allows the concurrent detection of several autoreactivities relevant to AIH. These include ANA, SMA, anti-LKM1, and anti-LC-1, as well as anti-mitochondrial antibody (AMA), the serological hallmark of primary biliary cholangitis, the presence of which weighs against the diagnosis of AIH (23–25,29), although rare cases of AMA-positive AIH have been reported, including in children (42–45). Long-term follow-up of these AMA-positive patients into adult life is warranted, as adults with AMA-positive AIH have been shown to develop clinical, biochemical, and histological features of primary biliary cholangitis up to 3 decades after first presentation (46).

Autoantibodies are considered positive when present at a dilution $\geq 1:40$ in adults, whereas in children, who are rarely positive for autoantibodies in health, positivity at a dilution $\geq 1:20$ for ANA and SMA or $\geq 1:10$ for anti-LKM1 is clinically significant (29). Both in adults and children, autoantibodies may be present at a low titer or even be negative at disease onset, particularly during acute or fulminant presentations, to become detectable during follow-up.

ANA is detectable on all rodent tissues and in AIH usually has a homogeneous pattern. For a clearer definition of the pattern, HEp2 cells that have prominent nuclei are used, but these cells are not recommended for screening purposes because of a high positivity rate in the normal population (29,47,48) and in the presence of infection, particularly in children (49).

There are no ANA molecular targets specific for AIH. Although ANA reactivities similar to those found in lupus erythematosus (nuclear chromatin, histones, centromere, single/double-stranded DNA, ribonucleoproteins) have been reported (50,51), approximately 30% of AIH patients positive for ANA do not react with known nuclear targets (50). Immunofluorescence remains therefore the criterion standard for ANA testing.

The immunofluorescent staining of SMA is detected in the arterial walls of rodent kidney, liver, and stomach. In the kidney, SMA can have 3 patterns: V (vessels), G (glomeruli), and T (tubules) (29). The V pattern is present in nonautoimmune inflammatory liver disease, in autoimmune diseases not affecting the liver and in viral infections, but the VG and VGT patterns are indicative of AIH. The VGT pattern corresponds to the ‘‘F actin’’ or microfilament pattern observed using cultured fibroblasts as substrate. The molecular target of the microfilament reactivity remains to be identified. Although anti-actin reactivity is strongly associated with AIH, approximately 20% of AIH-1 patients do not possess anti-actin antibodies (29).

The anti-LKM1 pattern is characterized by bright staining of the hepatocyte cytoplasm and of the P3 portion of the renal tubules. Anti-LKM1 can be confused with AMA, as both autoantibodies stain liver and kidney, although AMA, in contrast to anti-LKM1, also stains gastric parietal cells. The identification of the molecular targets of anti-LKM1, cytochrome P4502D6, and of AMA, enzymes of the 2-oxo-acid dehydrogenase complexes, has allowed the establishment of immunoassays using recombinant or purified antigens (29), which can be used to resolve doubtful cases.

Anti-LC-1, an additional marker for AIH-2, can be present on its own, but frequently occurs in association with anti-LKM1, and targets formimino-transferase cyclodeaminase (52). Anti-formimino-transferase cyclodeaminase antibody can be detected by commercial enzyme-linked immunosorbent assay (29).

Other autoantibodies less commonly tested, but of diagnostic importance, include antisoluble liver antigen (anti-SLA) and antiperinuclear neutrophil cytoplasm (pANCA) antibodies.

Anti-SLA is highly specific for the diagnosis of AIH (50,51) and its presence identifies patients with more severe disease and worse outcome (53). At variance with standard diagnostic

autoantibodies, anti-SLA is not detectable by immunofluorescence. The discovery of the molecular target of anti-SLA as Sep (O-phosphoserine) tRNA:Sec (selenocysteine) tRNA synthase (SEP-SECS) (54) and its cloning has led to the availability of molecularly based diagnostic assays for anti-SLA.

In AIH-1, akin to primary sclerosing cholangitis and inflammatory bowel disease, pANCA are frequently detected, but they are atypical, as they are reported to react with peripheral nuclear membrane components, and are therefore also termed peripheral anti-nuclear neutrophil antibodies. In contrast to AIH-1, peripheral anti-nuclear neutrophil antibodies are virtually absent in AIH-2 (29).

A seronegative form of AIH responsive to steroid treatment has been reported in pediatric retrospective studies, at times associated with the development of aplastic anemia (55–57). In these reports, however, autoantibody testing has not been performed according to IAIHG guidelines. The true prevalence of AIH negative for all the autoantibodies listed above can only be established with a rigorous prospective study.

Clinical Features

As mentioned above, AIH is divided into 2 types according to its autoantibody profile: AIH-1 is positive for ANA and/or SMA, and AIH-2 for anti-LKM-1 and/or anti-LC-1. The prevalence of juvenile AIH is unknown. A recent study reports an annual incidence of pediatric AIH of 0.23 per 100,000 children in a large Canadian cohort (58). Data collected at the King's College Hospital Paediatric Hepatology tertiary referral centre show a 6-fold increase in the yearly incidence of juvenile AIH between the 1990s and 2000s (59), and a large study in Denmark shows a 2-fold increase in the incidence of adult AIH in the same period of time (60), suggesting either a better awareness of this condition, leading to an increased referral rate and diagnosis, and/or a real increase in the incidence of autoimmune liver disease.

Three quarters of patients with either type of AIH are female. AIH-1 affects all ages, with 2 peaks, one in childhood/adolescence and the other in adulthood around the age of 40 years. AIH-2 affects mainly children and young adults, being rare, although not absent, in older individuals. In pediatrics, AIH-1 accounts for at least two-thirds of the cases and presents usually during adolescence, whereas AIH-2 presents at a younger age, including during infancy. IgG are usually raised at onset in both types, although 15% of children with AIH-1 and 25% of those with AIH-2 have levels within the normal range, particularly when the disease presents acutely (61,62). Interestingly, also these children with IgG within the normal range experience a reduction in levels during treatment. Partial IgA deficiency is common in AIH-2, affecting approximately 40% of patients (61,63). Although most adult patients with AIH-1 have a chronic disease course with nonspecific symptoms such as fatigue, nausea, abdominal pain, and arthralgia (64), in children and adolescents, AIH has a more aggressive phenotype. Until recently, the clinical course of pediatric AIH has been mainly described in patients of European origin (31,61,65–70), individuals from other ethnic groups being considered rarely affected by this condition. This notion, however, is proving incorrect, as AIH has been recently reported in a diverse range of populations (56,57,71–78). In the largest mostly European cohorts, the mode of AIH presentation includes (31,40,58,61,76,79):

1. acute presentation resembling that of viral hepatitis, with nonspecific symptoms of malaise, nausea/vomiting, anorexia, joint and abdominal pain, followed by jaundice, dark urine, and pale stools (40%–50% of patients with AIH-1 or AIH-2)

2. FHF with grade II to IV hepatic encephalopathy developing 2 weeks to 2 months after the onset of symptoms (~3% of patients with AIH-1 and ~25% of patients with AIH-2)
3. insidious onset, characterized by nonspecific symptoms (progressive fatigue, relapsing jaundice, amenorrhea, headache, anorexia, joint and abdominal pain, diarrhea, weight loss), lasting from 6 months to a few years before diagnosis (~40% of patients with AIH-1 and ~25% of patients with AIH-2)
4. complications of cirrhosis and portal hypertension (hematemesis from oesophageal/gastric varices, bleeding diathesis, splenomegaly), without previous history of jaundice or liver disease (~10 of both AIH types).
5. incidental finding of raised hepatic aminotransferases, without any symptoms or signs (rare in large series, but real prevalence unknown)

The mode of presentation of AIH in childhood is therefore variable, and the disease should be suspected and excluded in all children presenting with symptoms and signs of prolonged or severe liver disease. Acute hepatitic episodes alternating with spontaneous clinical and biochemical improvement are not uncommon, a relapsing pattern that often leads to a dangerous delay in diagnosis and treatment. Hence, AIH should always be suspected when known causes of acute hepatitis are excluded.

At least one-third of patients with AIH have cirrhosis at the time of diagnosis, irrespective of the mode of presentation, (61,62), indicating that the disease process is longstanding. AIH patients presenting acutely have often advanced fibrosis or cirrhosis on liver biopsy.

Severity of disease is similar in the 2 AIH types. AIH-2, however, has a higher tendency to present as ALF and is more refractory to eventual treatment withdrawal (61,75,78). In both types, a family history of autoimmune disease is frequent (~40%) and approximately 20% of patients have associated autoimmune disorders either present at diagnosis or developing during follow-up, including thyroiditis, inflammatory bowel disease (IBD), hemolytic anemia, vitiligo, celiac disease, insulin-dependent diabetes, Behçet disease, Sjögren syndrome, glomerulonephritis, idiopathic thrombocytopenia, urticaria pigmentosa, hypoparathyroidism, and Addison disease (mainly in AIH-2) (61,80). These conditions should be actively sought for prompt treatment (81). In this context, diagnoses of particular importance are: thyroiditis with hypothyroidism that affects 8% to 23% of patients (61,80), celiac disease that affects 5% to 10% of patients (82–85), and IBD that is reported in 18% of patients (31). Interestingly, patients with AIH and celiac disease have been reported to achieve treatment-free sustained remission in a significantly higher proportion of cases, when compared with patients with AIH without celiac disease, suggesting a possible long-term adjuvant effect of the gluten-free diet (86).

AIH-2 responsive to immunosuppressive treatment can be part of the autoimmune polyendocrinopathy-candidiasis-ectodermal dystrophy syndrome, an autosomal recessive genetic disorder characterized by the triad of chronic mucocutaneous candidiasis, hypoparathyroidism, and Addison disease, in which AIH-2 is present in approximately 20% to 30% of cases (87–89). Autoimmune and immunodeficiency diseases are likely to be the outcome of a dysfunctional immune system. Multiple single-gene defects have been identified, resulting in rare diseases with features of both immunodeficiency and autoimmunity, including AIH (90–92).

As mentioned above, AIH is being increasingly reported in children and adolescents of non-Caucasoid descent, probably because the diagnosis of autoimmune liver disease was previously overlooked in view of the presence of epidemic viral hepatitis B and/or C. Reports from India (71,76), Malaysia (72), Pakistan (57),

Bahrain (73), Iran (56), Egypt (78), Jamaica (77), Mexico (75) on cohorts including between 5 and 181 (median 34) patients indicate a clinical presentation and response to immunosuppressive treatment similar to those described in Caucasoid patients, but an overall worse response to treatment and outcome, possibly related to delay in referral to specialized centers and diagnosis.

Treatment

Definition of Remission/Relapse

From the very early reports on pediatric AIH, the definition of treatment-induced remission has been much stricter than that used for the adult disease, in which for a long time transaminase levels up to twice the upper limit of normal were considered a sign of good response. In pediatric age, remission is defined as complete clinical recovery with transaminase levels within the

normal range and is achieved in 60% to 90% of patients (56,58,61,71,78), the rapidity and degree of the response to treatment depending on the disease severity at presentation. In more recent years, 3 more criteria have been added to the definition of remission: normalization of IgG levels, negative or very low-titer autoantibodies, and histological resolution of inflammation (62). The histological response, however, lags behind the biochemical response (93–95) and clinical/biochemical/immunological remission does not always reflect histological resolution, although 95% of patients have a marked histological improvement after a mean duration of 4 years of effective treatment (93). As liver biopsy cannot be repeated frequently, for clinical purposes, remission is considered complete when transaminase and IgG levels are normal, ANA and SMA are negative or low-titer (<1:20), and anti-LKM1 and anti-LC-1are <1:10 or negative (Fig. 1 and Table 1).

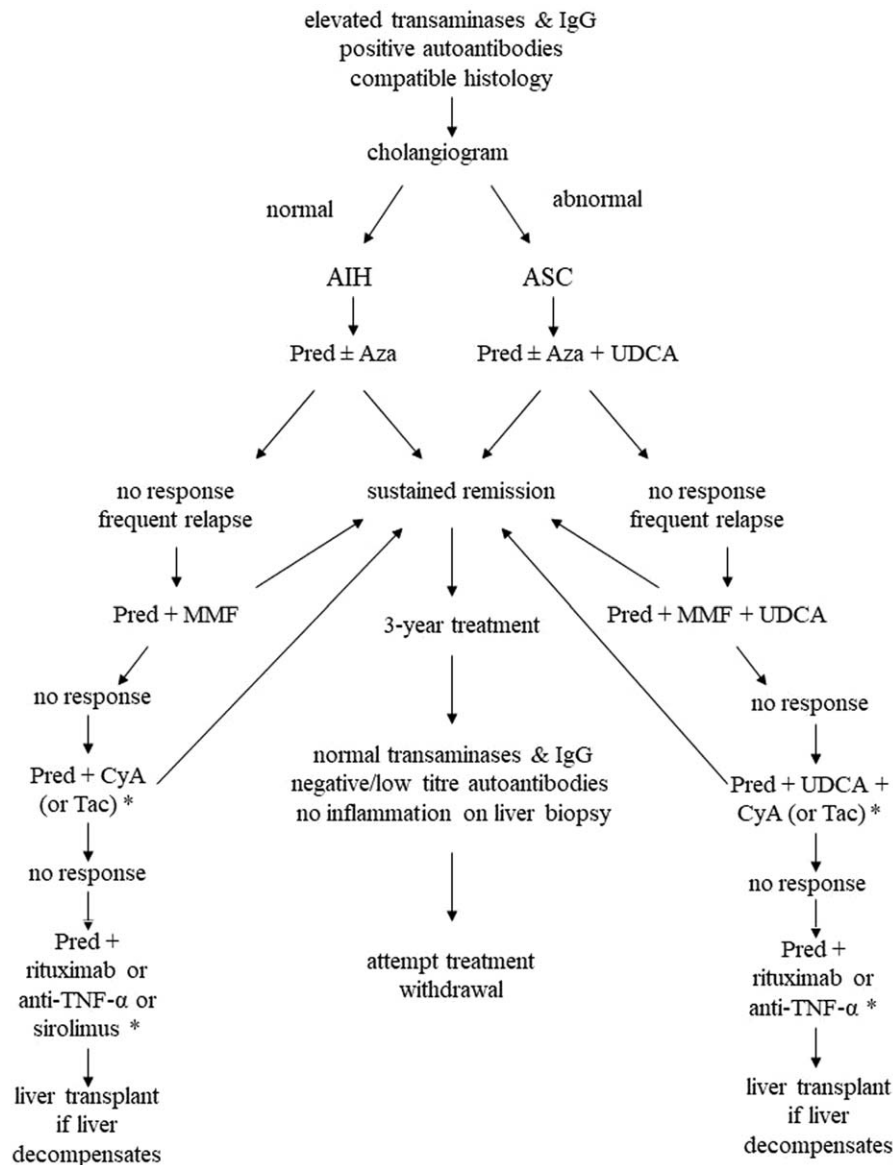


FIGURE 1. Flow chart for treatment decision making in children with autoimmune liver disease. *Second- and third-line treatments to be decided and monitored only in specialized pediatric hepatology centers. (Modified from (62)).

TABLE 1. Immunosuppressive treatment regimens for juvenile autoimmune liver disease

AIH	Initial regimen			Maintenance			Definition of remission	Treatment length	Before attempting treatment withdrawal
	Predni(so)lone	Azathioprine	Predni(o)lone	Azathioprine	Azathioprine mono-therapy (in AIH-1)				
AIH	2 mg · kg ⁻¹ · day ⁻¹ (up to 60 mg/daily) decreased weekly in parallel to transaminase levels decrease to a minimum maintenance dose of 2.5 to 5 mg daily	1–2 mg · kg ⁻¹ · day ⁻¹ added gradually if transaminase levels plateau or increase. Alternatively, added in all patients after 2 weeks of predniso(lo)ne treatment	0.1–0.2 mg · kg ⁻¹ · day ⁻¹ or 5 mg/day	1–2 mg/kg/day if required	1.2–1.6 mg/kg/day	Normal transaminase and IgG levels; - Negative or low titer (< 1:20) ANA/ SMA -negative anti-LKM-1/anti-LC-1	3 y Before considering suspension	Remission for at least 3 years + follow up liver biopsy showing no inflammatory changes	
ASC	Predniso(lo)ne ± azathioprine as above, plus ursodeoxycholic acid 15 mg/Kg/day		Predniso(lo)ne ± azathioprine as above, plus ursodeoxycholic acid 15 mg · kg ⁻¹ · day ⁻¹			As above	As above	As above	

AIH = autoimmune hepatitis; ANA = anti-nuclear antibody; ASC = autoimmune sclerosing cholangitis; SMA = anti-smooth muscle antibody.

Relapse is characterized by increase of serum aminotransferase levels after remission has been achieved. Relapse during treatment is common, occurring in about 40% of patients and requiring a temporary increase in the steroid dose. An important element in relapse is played by nonadherence, which is common, particularly in adolescents (72,96). In more aggressive cases, the risk of relapse is higher if steroids are administered on an alternate-day schedule, which is often instituted in the assumption that may have a less negative effect on the child’s growth. Small daily doses, however, are more effective in maintaining disease control and minimize the need for high-dose steroid pulses during relapses (with the consequent more severe side effects) and do not affect final height (97).

When to Treat

AIH should be suspected and sought in all children with evidence of liver disease after exclusion of infectious and metabolic etiologies. AIH is exquisitely responsive to immunosuppression and treatment should be initiated promptly to avoid progression of disease. The goal of treatment is to reduce or eliminate liver inflammation, to induce remission, improve symptoms, and prolong life expectancy (62,98,99). Although cirrhosis is present in between 44% and 80% of children at the time at diagnosis (61,68,93), mortality within childhood/adolescence is low and most children remain clinically stable and well on long-term treatment. A recent study on 30 children with autoimmune liver disease (AIH, primary sclerosing cholangitis [PSC], and ASC), however, reports a decreased health-related quality of life score in patients compared to healthy controls, the worse scores being found in those with complications of chronic liver disease, in particular ascites (100). In this study, however, 73% of the 30 patients investigated had advanced liver disease. It would be interesting to assess a larger and more representative cohort, including a higher proportion of those patients on long-term immunosuppression without liver-related complications, who represent the majority.

How to Treat

With the exception of a fulminant presentation with encephalopathy, AIH responds satisfactorily to immunosuppressive treatment whatever the degree of liver impairment, with a reported remission rate of up to 90% (31,58,61,76).

Standard Treatment (Table 1)

Conventional treatment of AIH consists of prednisolone (or prednisone) 2 mg · kg⁻¹ · day⁻¹ (maximum 60 mg/day), which is gradually decreased during a period of 4 to 8 weeks, in parallel to the decline of transaminase levels, to a maintenance dose of 2.5 to 5 mg/day (10,11,21,22,101). In most patients, an 80% decrease of the aminotransferase levels is achieved in the first 2 months, but their complete normalization may take several months (11,39). During the first 6 to 8 weeks of treatment, liver function tests should be checked weekly to allow frequent dose adjustments, avoiding severe steroid side effects. The timing for the addition of azathioprine as a steroid-sparing agent varies according to the protocols used in different centers. In some, azathioprine is added only in the presence of serious steroid side effects, or if the transaminase levels stop decreasing on steroid treatment alone, at a starting dose of 0.5 mg · kg⁻¹ · day⁻¹. In the absence of signs of toxicity, the dose is increased up to a maximum of 2.0–2.5 mg · kg⁻¹ · day⁻¹ until biochemical control is achieved. In other centers, azathioprine is added at a dose of 0.5 to 2 mg · kg⁻¹ · day⁻¹

after a few weeks (usually 2 weeks) of steroid treatment. Whatever the protocol, 85% of the patients eventually require the addition of azathioprine. Some centers use a combination of steroids and azathioprine from the beginning (70), but caution is recommended with this approach because azathioprine can be hepatotoxic, particularly in cirrhotic and severely jaundiced patients (22). A recent retrospective analysis of patients treated with a combination of azathioprine and prednisolone from diagnosis reports more side effects (93%) and a higher relapse rate (67%) (102) than what observed in AIH children treated with steroid induction followed by azathioprine addition only when indicated (relapse rate 33%–36%; side effects 18%–38%) (31,61).

Measurement of thiopurine methyltransferase (TPMT) activity level before initiating azathioprine therapy has been proposed as a predictor of drug metabolism and toxicity (39), although, at least in adult patients, advanced fibrosis, but not TPMT genotype or activity, was able to predict azathioprine toxicity in AIH (103). Measurement of the azathioprine metabolites 6-thioguanine (6-TGN) and 6-methylmercaptopurine has been reported to help in identifying drug toxicity and nonadherence and in achieving a level of 6-TGN considered therapeutic for inflammatory bowel disease (104), although an ideal therapeutic level for AIH has not been determined. In a recent retrospective review, 87% of 66 children with AIH were reported to maintain sustained biochemical remission (normal transaminase levels) in association with low 6-TGN levels ranging from 50 to 250 pmol on an azathioprine dose of 1.2 to 1.6 mg · kg⁻¹ · day⁻¹ (105). Moreover, the same report shows that remission can be maintained on low-dose azathioprine monotherapy in AIH-1 (105).

Alternative Treatments

Alternative AIH treatments have been proposed: to induce remission at disease onset in an attempt to decrease steroid side effects; to treat refractory patients, that is, those intolerant of or unresponsive to standard immunosuppression, often referred to as “difficult-to-treat”.

For Induction of Remission

An attractive drug for the induction and maintenance of remission in AIH is budesonide, a drug with hepatic first-pass clearance of >90% of the oral dose and fewer side effects than prednisolone, representing an ideal “topical” liver treatment, more acceptable to patients (106). A drawback is that it cannot be used in the presence of cirrhosis, which affects at least one-third of AIH patients. In a large European trial, comprising 160 adult and 46 pediatric patients, a combination of budesonide and azathioprine was compared with a combination of prednisone and azathioprine (107). Remission was defined as normal transaminase levels without steroid side-effects. The effect of budesonide at a dose of 3 mg 3 times daily, decreased upon response, was compared with that of prednisone 40 mg once daily reduced per protocol, irrespective of response, for 6 months; then budesonide was given to all patients for further 6 months. When both the adult and pediatric cohorts were analyzed together, after 6 months of treatment, remission was achieved in 60% of the budesonide group but in only 39% of the prednisone group, suggesting that the combination budesonide/azathioprine is more effective than prednisone/azathioprine. The results among the children recruited into the study, however, were disappointing, with a similarly low remission rate of 16% for budesonide/azathioprine and 15% for prednisone/azathioprine after 6 months of treatment and of 50% and 42%, respectively, after 12 months of

treatment, with similar steroid side-effects in both groups, apart from a higher frequency of weight gain in children on prednisone (108). As these remission rates are much poorer than those achieved with the standard treatment schedule, caution is advisable in using budesonide to induce remission in juvenile AIH (59). A controlled trial in a larger number of treatment-naïve pediatric AIH patients, using a study design that includes strict diagnostic criteria and drug schedules appropriate for the juvenile disease, is needed to establish whether budesonide has a role in the treatment for this condition.

Induction of remission has been obtained in treatment-naïve children using cyclosporine A alone for 6 months, followed by the addition of prednisone and azathioprine; 1 month later, the cyclosporine was discontinued (109,110). Cyclosporine was used at the dose of 4 mg · kg⁻¹ · day⁻¹ in 3 divided doses, increased if necessary every 2 to 3 days to achieve a whole blood concentration of 250 ± 50 ng/mL for 3 months. If there was clinical and biochemical response in the first months, cyclosporine was reduced to achieve a concentration of 200 ± 50 ng/mL for the following 3 months, before discontinuing it. This protocol has been used with success in a small number of children with AIH in Croatia (111). Whether this mode of induction has any advantage over the standard treatment, however, has yet to be evaluated in controlled studies. Tacrolimus, a more potent immunosuppressive agent than cyclosporine with similar drug class toxicity, has anecdotally been used to induce remission in adults with AIH. Its use in the juvenile form of the disease is limited to one report, where tacrolimus was administered to 17 children with newly diagnosed AIH with or without the addition of prednisolone and/or azathioprine, and to 3 children who had failed conventional therapy. Target tacrolimus trough levels were relatively low (2.5–5 ng/mL) and similar to those used in the maintenance of successful liver transplant. Although the study shows that monotherapy with tacrolimus is not sufficient to achieve complete remission in most cases, the calcineurin inhibitor is reported to allow reduction of the dose of prednisolone and azathioprine, avoiding their side-effects. Ten patients developed headache and/or recurrent abdominal pain while on tacrolimus, although they did not require stopping treatment, whereas 2 patients stopped tacrolimus, one because of the development of IBD and the other because of deterioration of liver function requiring liver transplantation (LT) (112).

For Refractory Cases

A promising drug for difficult-to-treat patients is mycophenolate mofetil (MMF), the prodrug of mycophenolic acid. In juvenile AIH patients in whom standard immunosuppression is unable to induce stable remission, or who are intolerant to azathioprine, MMF at a dose of 20 mg/kg twice daily, together with prednisolone, has been used successfully (113). A recent meta-analysis, including data from several small, even anecdotal, studies of second-line treatments in children refractory to standard therapy suggests that calcineurin inhibitors might have the highest response rate at 6 months, but also have the highest rate of adverse events; MMF was the second most effective drug with a low side-effect profile, supporting the notion that MMF should be the primary choice for second-line therapy in AIH children refractory to standard treatment (114). If there is a persistent absence of response or if there is intolerance for MMF (headache, diarrhea, nausea, dizziness, hair loss, and neutropenia), the use of calcineurin inhibitors should be considered (Table 2).

Anecdotal experience with the successful use of the anti-B lymphocyte monoclonal antibody rituximab in 2 children with refractory AIH has been reported (115). Despite the relatively low adverse event profile of the drug, however, its use has been

TABLE 2. Alternative treatments for juvenile autoimmune liver disease

Agent	Pros	Cons
Mycophenolate mofetil	Favorable toxicity profile Experience in the transplant setting	Contradictory reports regarding its efficacy Teratogenicity
Tacrolimus	Potent immunosuppressant Experience in the transplant setting	Anecdotal experience Unclear efficacy Renal toxicity
Cyclosporine	Potent immunosuppressant Experience in the transplant setting	Unclear benefit over standard treatment Cosmetic effects Renal toxicity
Budesonide	High first pass metabolism in the liver	Ineffective in cirrhotic patients Less effective as first line treatment compared to standard treatment
Rituximab	Relatively favorable toxicity profile	Infectious complications Anecdotal experience Unclear efficacy
Infliximab	Potent immunomodulatory properties Effective in inflammatory bowel disease	Unclear efficacy in liver disease Infectious complications Paradoxical development of AIH
Ursodeoxycholic acid	Putative immunomodulatory capacities Choleretic	Efficacy yet to be demonstrated

AIH = autoimmune hepatitis.

associated to a 2.4% rate of sepsis in children with autoimmune diseases (116).

Infliximab has been reported to be effective in the treatment of refractory AIH, including in a pediatric case (117,118). Its use as a rescue treatment, however, should be carefully evaluated in view of the potential serious infectious side-effects already reported, including hepatotoxicity (117). Moreover, anti-tumor necrosis factor (TNF)- α -induced AIH has been reported in adults and children treated for inflammatory bowel disease or other autoimmune conditions (119,120). Better understanding of the role of TNF- α in the pathogenesis of AIH is needed before recommending its use in AIH.

As patients with AIH have a defect in immunoregulation affecting regulatory T cells (121), sirolimus, a drug that selectively expands regulatory T cells in vivo and in vitro (122) has been used in 4 patients with refractory AIH, with short-term beneficial effect in 2 of them (123).

Interestingly, a recent survey on management of juvenile AIH commissioned by the IAIHG (124) has shown that among the pediatric IAIHG members there is considerable more experience with second-line therapeutic agents, than among the IAIHG adult hepatologist members (125).

Fulminant Hepatic Failure Presentation

The management of AIH presenting with FHF, that is, with hepatic encephalopathy, is controversial. In adults, corticosteroid therapy is reported to be of little benefit in AIH FHF and to favor septic complications (126). In a recent pediatric cohort, prednisone treatment has led to the recovery of 4 of 9 children with AIH FHF referred to a transplant centre, the other 5 requiring liver transplant despite steroids (40). In that article, AIH was diagnosed on the basis of positivity for autoantibodies and raised immunoglobulin G. Although liver histology was also obtained, it did not differentiate AIH FHF from cryptogenic FHF, highlighting the fact that liver biopsy in FHF is not only dangerous, because of severe coagulopathy, but also does not provide diagnostic information. Similarly, good results with steroid therapy are reported in an article from

India, wherein 10 of 13 patients with severe acute presentation of AIH, including encephalopathy in 6, were rescued by prednisone treatment (76).

In a recent publication by The American Pediatric Acute Liver Failure Study Group (PALFSG), at least 1 autoantibody was tested in 722 of 986 patients recruited and found to be positive in 28%. Autoantibodies were present not only in children diagnosed as having AIH, but also in some with indeterminate ALF or Wilson disease (127). Autoantibody-positive and autoantibody-negative patients had similar outcomes, although children positive for anti-LKM were younger and more likely to undergo LT compared to the other autoantibody positive patients. The authors conclude that the significance of autoantibody positivity in the context of pediatric ALF is uncertain, although positivity for anti-LKM identifies children with a particularly poor prognosis. Major limitations of this study, however, are the lack of systematic testing for autoantibodies diagnostic for AIH using reliable techniques (29) in the whole cohort, and lack of information on treatment. Prospective studies with a rigorous protocol for testing AIH serology and for clinical management of AIH are necessary to clarify the role of steroids in the context of severe acute or fulminant disease.

When and How to Stop Treatment

In pediatric AIH, current recommendation is to treat children for at least 2 to 3 years and to attempt withdrawal of treatment only if transaminase and IgG levels have been normal and autoantibody-negative (or at maximum titer of 1:20 by immunofluorescence on rodent tissue for ANA/SMA) for at least a year. A liver biopsy should be repeated before deciding to attempt treatment cessation, as residual inflammatory changes, even with normal blood tests, herald relapse (21,22,62). Following this protocol, successful long-term complete withdrawal of treatment was possible in 20% of patients with AIH-1, but not in AIH-2, relapse while attempting withdrawal affecting 45% (31). A recent retrospective review, which includes also a fair proportion (21.4%) of children with AIH/sclerosing cholangitis overlap (who have a different response

to treatment, see below), reports successful withdrawal of immunosuppression in 14 of 16 patients with AIH-1 in whom withdrawal was attempted, but in none with AIH-2. Failure to suspend immunosuppression successfully was associated to elevated international normalized ratio, positive anti-neutrophil cytoplasmic antibody titer, cirrhosis, and presence of nonhepatic autoimmune disorders (66). These encouraging results in juvenile AIH contrast with reports in the adult population (128) possibly because of lack of strict criteria before attempting treatment withdrawal in the latter.

AUTOIMUNE SCLEROSING CHOLANGITIS

Sclerosing cholangitis is a chronic inflammatory disorder that affects the intrahepatic and/or extrahepatic biliary tree leading to bile duct and liver fibrosis. The diagnosis is based on typical bile duct lesions being visualized on cholangiography. With the growing use of noninvasive biliary imaging, sclerosing cholangitis, hitherto considered rare in children, is diagnosed with increasing frequency in pediatric age. It is an important cause of morbidity and mortality, accounting for approximately 2% of the pediatric liver transplants in the United States between 1988 and 2008 (United Network for Organ Sharing Data Report—October 2009. <http://www.unos.org/data/>).

Sclerosing cholangitis in children/adolescents is widely referred to as PSC, borrowing the adult definition. There are important differences, however, between adult PSC and juvenile sclerosing cholangitis (129).

“Primary” denotes ignorance about etiology and pathogenesis, whereas in pediatrics, there are well-defined forms of sclerosing cholangitis, including biliary atresia and autosomal recessive neonatal sclerosing cholangitis. Other inherited conditions, for example, mild to moderate defects in the *ABCB4* (MDR3) gene, are being increasingly recognized as a possible cause of small duct sclerosing cholangitis in both children and adults (130). Sclerosing cholangitis may also complicate a wide variety of disorders, including primary and secondary immunodeficiencies, Langerhans cell histiocytosis, psoriasis, cystic fibrosis, reticulum cell sarcoma, and sickle cell anemia. An overlap syndrome between AIH and sclerosing cholangitis (ASC) is more common in children than in adults. Although the name ASC is not universally accepted, it is becoming increasingly more used by both the pediatric and adult hepatology community. Only in those pediatric patients in whom sclerosing cholangitis occurs without any of the above defining features, the name of “primary” would be appropriate.

The only published prospective study aiming at defining the prevalence of ASC versus AIH in children has shown that when cholangiographic studies are performed at presentation, ASC is as prevalent as AIH-1 (31). In this study, clinical features of ASC compared to AIH include:

1. 50% of the patients with ASC are male.
2. Abdominal pain, weight loss, and intermittent jaundice, are frequent presenting symptoms in both ASC and AIH-1.
3. IBD affects about 45% of children with ASC, and about 20% of those with AIH.
4. Virtually all ASC patients are seropositive for ANA and/or SMA.
5. 90% of children with ASC have greatly increased serum IgG levels.
6. Standard liver function tests do not help in discriminating between AIH and ASC at presentation.
7. The IAIHG scoring systems do not discriminate between AIH and ASC.
8. pANCA is present in 75% of patients with ASC in comparison with 45% of patients with AIH type 1 and 10% of those with AIH type 2.

Thus, in contrast to AIH, ASC affects equally males and females. Almost all patients with ASC have autoimmune serology and histological characteristics similar to AIH-1 (Table 3). The differential diagnosis between AIH and ASC is achieved only by cholangiographic studies, which show evidence of bile duct disease, usually from disease onset. Of note, alkaline phosphatase and gamma glutamyl transpeptidase levels—usually elevated in cholestatic disease—are often normal or only mildly increased in the early disease stages of ASC, although the alkaline phosphatase/AST ratio is significantly higher in ASC than in AIH. One-quarter of the children with ASC, despite abnormal cholangiograms, have no histological features suggesting bile duct involvement; conversely, 27% of the patients with AIH have biliary features on histology (including bile duct damage, acute and/or chronic cholangitis, biliary periportal hepatitis) (31). The overlap of histological features between AIH and ASC has been confirmed in a recent study (131). It is noteworthy that neither the original nor the simplified IAIHG scoring systems (23–25) are suitable to discriminate between AIH and ASC, as they do not include cholangiographic studies at disease onset. ASC is therefore frequently diagnosed and treated as AIH-1 and the presence of sclerosing cholangitis may be discovered during follow-up, after the appearance of an overt cholestatic biochemical profile. In view of the inadequacy of the published IAIHG scoring systems in distinguishing between AIH and ASC, a scoring system for juvenile autoimmune liver disease is proposed in Table 4. This scoring system will need validation. The prospective study alluded to above shows that if treatment is started early, the parenchymal liver damage in ASC responds well in terms of normalization of biochemical and immunological parameters to the same immunosuppressive treatment used for AIH, with good medium to long-term survival. The bile duct disease, however, progresses in about 50% of patients despite treatment (31), particularly in those with associated difficult to control IBD. In a retrospective study aiming at comparing the response to treatment and outcome of children with AIH and ASC, no difference is reported between the two groups of patients, with a good response to prednisolone ± azathioprine in both (132). In contrast to the prospective study, however, in this article, the diagnosis of ASC was only made in those patients developing cholestatic manifestations during follow-up; no cholangiographic studies having been performed at presentation, making the comparison between the 2 studies unfeasible.

Ursodeoxycholic acid (UDCA) treatment was added to immunosuppression in the prospective study (31), but whether it has any role in arresting the progression of the bile duct disease remains to be established. In adults with primary sclerosing cholangitis, high-dose UDCA has been reported as more beneficial than standard doses (133), but a randomized double-blind controlled study shows that high-dose UDCA has a negative long-term effect (134). It is prudent, therefore, to use doses not $>15 \text{ mg} \cdot \text{kg}^{-1} \cdot \text{day}^{-1}$.

Most of the other published series of pediatric sclerosing cholangitis are retrospective studies from single centers, based on small patient numbers, with the exception of a recently published retrospective multicenter large cohort of juvenile sclerosing cholangitis (135). In these reports, the incidence of the various clinical forms of sclerosing cholangitis differs depending upon the year of publication and the center where the study was conducted, reflecting different study designs, patterns of referral and diagnostic protocols. In all these retrospective series, cholangiographic studies were prompted by biochemical and/or histological features of cholestatic disease. In all, boys are more affected than girls; 20% to 40% of patients have intrahepatic cholangiopathy with normal extrahepatic bile ducts, and there is a strong association with IBD, which is described in 60% to 90% of cases according to study

TABLE 3. Comparison between AIH-1, AIH-2, and ASC

Variable	AIH-1	AIH-2	ASC
Female sex	80%	80%	50%
Male sex	20%	20%	50%
ANA or SMA*			
≥1:20	++	+/-	++
Anti-LKM-1*			
≥1:10	-	++	+/-
Anti-LC-1			
Positive	-	++	-
Anti-SLA			
Positive	+	+	+
pANNA			
Positive	+	-	++
IgG			
>Upper limit of normal	++	+	++
>1.20 Times upper limit of normal	++	+	++
Liver histology			
Compatible with AIH	+	+	+
Typical of AIH	+	+	+
Viral hepatitis (A, B, C, E, EBV), NASH, Wilson disease, and drug exposure	-	-	-
Presence of extrahepatic autoimmunity	+	+	+
Family history of autoimmune disease	+	+	+
Cholangiography			
Normal	+	+	-
Abnormal	-	-	+
Biochemical and immunological response to steroid treatment			
Yes	+	+	+
No	-	-	-

AIH-1 = autoimmune hepatitis type 1; AIH-2 = autoimmune hepatitis type 2; ANA = anti-nuclear antibody; anti-LC-1 = anti-liver cytosol type 1; anti-LKM-1 = anti-liver kidney microsomal antibody type 1; anti-SLA = anti-soluble liver antigen; ASC = autoimmune sclerosing cholangitis; EBV = Epstein-Barr virus; IgG = immunoglobulin G; NASH = nonalcoholic steatohepatitis; pANNA = peripheral anti-nuclear neutrophil antibodies; SMA = anti-smooth muscle antibody.

*Antibodies measured by indirect immunofluorescence on a composite rodent substrate (kidney, liver, stomach).

design. More than two-thirds of the patients have ulcerative colitis, the others having indeterminate colitis or Crohn disease. IBD can precede the diagnosis of liver disease by many years, be diagnosed at the same time, or develop during follow-up.

In all retrospective studies, a variable proportion of patients have ASC, but whereas in some, this condition is reported to respond favorably to treatment with immunosuppression, having a better prognosis than PSC (67, 136–138); in others, the prognosis of ASC is reported to be severe and not ameliorated by immunosuppressive treatment (139) or similar to that of PSC irrespective of treatment (135,140–142). Major limitations of all these retrospective studies are uneven diagnostic protocols and lack of accurate information on the treatment of IBD before the diagnosis of sclerosing cholangitis, as immunosuppression for IBD might have an effect also on the presentation and course of the liver disease. Thus, as shown by the prospective study, which is often cited negatively to support a worse prognosis for ASC compared to AIH, immunosuppressive treatment is effective in controlling both parenchymal and biliary disease in 50% of ASC cases (31), suggesting that the real prognosis of ASC compared to PSC cannot be adequately established in retrospective cohorts with variable diagnostic approaches and treatment protocols.

Recently, it has been suggested that the chronic IBD associated with ASC may represent a distinct nosologic entity, different from classic ulcerative colitis and Crohn disease, being characterized by right-sided colitis with frequent rectal sparing, and small bowel mucosal breaks on capsule enteroscopy (143).

Multicenter prospective studies are needed for defining hepatic and intestinal phenotype of ASC, for establishing diagnostic criteria and for exploring pathogenic mechanisms with the aim of devising more effective forms of treatment.

LIVER TRANSPLANTATION FOR PEDIATRIC AUTOIMMUNE LIVER DISEASE

LT is a treatment option for AIH and ASC patients with end-stage chronic liver disease, hepatic malignancy, or intractable symptoms, as well as for AIH patients presenting with severe ALF unresponsive to steroid treatment.

AIH accounts for 2% to 5% of pediatric LTs performed in Europe and the United States (21,144). The transplant rate for AIH is variable, ranging from 9% to 55%, the interval between presentation and transplantation being as short as days in case of fulminant presentation to several years after diagnosis (61,65,67,145). These different transplant rates are likely to depend on several factors: expertise of the reporting center (primarily transplant or hepatology unit), type of survey (single center or population-based), late referral/treatment, missed diagnosis of ASC, different ethnic background. The reported 5-year survival rate after LT for AIH is excellent, being 80% to 90% (146).

Sclerosing cholangitis accounts for 2% to 3% of LTs performed in pediatric-aged patients (147) (United Network for Organ Sharing Data Report—October 2009. <http://www.unos.org/data/>) only some of whom have ASC (129). Overall, LT rate for sclerosing

TABLE 4. Proposed scoring criteria for the diagnosis of juvenile autoimmune liver disease

Variable	Cut-off	Points	
		AIH	ASC
ANA and/or SMA*	≥1:20 [†]	1	1
	≥1:80	2	2
Anti-LKM-1* or	≥1:10 [†]	1	1
	≥1:80	2	1
Anti-LC-1	Positive [†]	2	1
Anti-SLA	Positive [†]	2	2
pANNA	Positive	1	2
IgG	>ULN	1	1
	>1:20 ULN	2	2
Liver histology	Compatible with AIH	1	1
	Typical of AIH	2	2
Absence of viral hepatitis (A, B, E, EBV), NASH, Wilson disease, and drug exposure	Yes	2	2
Presence of extrahepatic autoimmunity	Yes	1	1
Family history of autoimmune disease	Yes	1	1
Cholangiography	Normal	2	-2
	Abnormal	-2	2

Score ≥7: probable AIH; ≥8: definite AIH. Score ≥7: probable ASC; ≥8: definite ASC. AIH = autoimmune hepatitis; ANA = anti-nuclear antibody; anti-LC-1 = anti-liver cytosol type 1; anti-LKM-1 = anti-liver kidney microsomal antibody type 1; anti-SLA = anti-soluble liver antigen; ASC = autoimmune sclerosing cholangitis; EBV = Epstein-Barr virus; IgG = immunoglobulin G; NASH = nonalcoholic steatohepatitis; pANNA = peripheral anti-nuclear neutrophil antibodies; SMA = anti-smooth muscle antibody; ULN = upper limit of normal.

*Antibodies measured by indirect immunofluorescence on a composite rodent substrate (kidney, liver, stomach).

[†]Addition of points achieved for ANA, SMA, anti-LKM-1, anti-LC-1, and anti-SLA autoantibodies cannot exceed a maximum of 2 points.

cholangitis ranges between 15% and 45%, and the interval between diagnosis and LT ranges from 6 to 12 years (67,139–141,148). In the King's College Hospital prospective study, 4 of 27 patients with ASC underwent LT during the 16-year study period (31), although it is likely that the rate of LT will increase when the long-term outcome and transition into adulthood data will be analyzed (149).

Recurrence of Autoimmune Hepatitis After Liver Transplantation

Despite the good outcome of transplantation for AIH, the disease can recur in the allograft despite immunosuppression (150–154). The reported recurrence rate is variable and depends on the criteria used for diagnosis, the immunosuppressive regimen, length of follow-up, and performance of “per protocol” biopsies. Mean time from LT to recurrence is 5 years (21,155), and recurrence rate increases with the postsurgery interval, but it may occur as early as 35 days after LT (156). The reported recurrence rates in children transplanted for AIH vary from 38% to 83% (65,145,157).

The diagnosis of recurrent AIH is based on the reappearance of clinical symptoms and signs, elevation of transaminase and IgG levels, autoantibodies, and interface hepatitis, along with response to prednisolone and azathioprine (21,158). These criteria are basically those included in the IAIHG scoring systems (23–25) used to diagnose AIH in the native liver. Although they have not been tested systematically for the diagnosis of recurrent AIH, they may provide a useful diagnostic tool in view of the similarity between AIH in the native liver and recurrent disease in the allograft.

Features reported to be associated with recurrence of AIH after LT are: possession of either human leukocyte antigen (HLA)–D-related antigen 3 (DR3) or –D-related antigen 4 (DR4) by the recipient (159,160); discontinuation of corticosteroids after

transplantation (161–163) (therefore caution should be exercised in weaning patients off immunosuppression); the severity of necroinflammatory activity in the native liver at the time of LT (156,164). Interestingly, recurrent AIH is reported to develop less frequently in patients transplanted for ALF compared to those with a chronic presentation (165). Although early studies pointed to an association between tacrolimus-based immunosuppression and the risk of AIH recurrence (156,166), a systematic review reported that primary immunosuppression with either cyclosporine or tacrolimus did not influence the risk of recurrence (167). Most transplant recipients with recurrent AIH respond to reintroduction or an increase in the dose of corticosteroids and azathioprine, which should be implemented as soon as the diagnosis is made. In the case of treatment failure, alternatives include addition of MMF in lieu of azathioprine to the standard therapeutic regimen (23–25), replacement of tacrolimus with cyclosporine (168), and replacement of calcineurin inhibitors with sirolimus.

Recurrent disease, particularly if not diagnosed and not treated promptly, may have serious consequences on graft function. In the first pediatric report, of the 5 patients who developed recurrent AIH, 3 progressed to end-stage liver disease requiring retransplantation (157). In a series from Birmingham, UK, none of the patients with AIH-1 who developed recurrence progressed to graft failure, whereas 80% of patients originally transplanted for AIH-2 required retransplantation (65). Further support to the negative impact of disease recurrence on allograft survival comes from a United Network for Organ Sharing database; of 174 children with AIH transplanted between 2002 and 2012, 19% lost the graft because of recurrent disease (169). Successful management of recurrent AIH relies greatly on its early diagnosis and prompt treatment. As histologic evidence can precede clinical evidence of recurrence, it might be useful to include a follow-up liver biopsy in the protocol for the management of patients transplanted for AIH (155,170).

Recurrence of Sclerosing Cholangitis after Liver Transplantation

Recurrence of sclerosing cholangitis after pediatric LT has been reported between 10% to 50% of recipients without distinction of the form of sclerosing cholangitis leading to transplantation (140,141,149,171), the wide range depending on the length of follow-up, as the risk for recurrence increases over time.

The diagnosis of recurrent sclerosing cholangitis is suggested by histological and/or cholangiographic findings of bile duct disease. Suggestive histological findings include presence of fibrous cholangitis, fibro-obliterative lesions with or without ductopaenia, fibrosis or cirrhosis, and/or interface hepatitis, whereas the cholangiography generally shows diffuse biliary structuring (172). Other causes of nonanastomotic biliary strictures in the graft should be carefully excluded, including ischemic biliary insults (eg, as consequence of hepatic artery thrombosis), ABO incompatibility between donor and recipient, bacterial or fungal cholangitis, and chronic ductopaenic rejection (173). No consistent risk factors have been reported in association to the development of recurrent sclerosing cholangitis. Some pediatric studies point to an association between active IBD after LT and the development of recurrent disease (141,149). Similarly, a study in adult patients transplanted for PSC shows that persistent ulcerative colitis requiring maintenance steroids is associated to an increased risk of developing recurrent disease in the graft, whereas colectomy before or during LT conferred protection against the development of recurrent disease (174).

There is no established treatment for recurrent sclerosing cholangitis after pediatric LT. If dominant strictures are present, they should be dilated by interventional cholangiographic means whenever possible (175).

Ursodeoxycholic acid treatment has been advocated in the setting of transplanted adult PSC patients because it seems to improve biochemical indices of liver disease, but it remains unknown whether it has an impact on outcomes (175).

Although in adults the effect of recurrence of sclerosing cholangitis on graft survival is controversial, in pediatrics, recurrent disease, particularly in the context of ASC, is associated with seriously compromised graft survival: in the King's College Hospital prospective study, two-thirds of patients who experienced recurrent disease eventually required re-transplantation (149).

De novo Autoimmune Hepatitis After Pediatric Liver Transplantation

De novo AIH after LT affects patients transplanted for disorders other than autoimmune liver disease. Although nonspecific development of autoantibodies over time after liver transplantation is common, affecting >70% of recipients (150,176), the prevalence of de novo AIH in children ranges from 2% to 6% (151,152,177–181). The condition was first reported in a pediatric cohort, affecting 4% of children transplanted in a single center for various nonautoimmune conditions (177). The patients developed a form of graft dysfunction with features identical to those of classical AIH, namely, high transaminase levels, hypergammaglobulinemia, positivity for autoantibodies—ANA, SMA, typical and atypical anti-LKM-1 (ie, staining renal tubules only)—and histological features of chronic hepatitis with portal/periportal inflammation and centrilobular necrosis. Other causes of post-LT graft dysfunction, such as rejection, infection, and hepatic artery thrombosis, were excluded. Patients with de novo AIH did not respond to conventional antirejection treatment, but only to the classical treatment of AIH. None of the children had undergone transplantation for autoimmune conditions and all had serum concentration of

calcineurin inhibitor within therapeutic antirejection levels at the time of de novo AIH diagnosis. Since that report, several other groups have reported the occurrence of de novo AIH after both pediatric and adult LT. De novo AIH has been described also as a complication of living donor LT recipients (182). In the largest study published to date in children, describing 41 (5.2%) patients out of 788 LTs performed at a single center, who developed de novo AIH, rejection and steroid dependence were identified as risk factors for the development of this complication (181). In adults, it has been suggested that a histologic pattern of centrilobular injury characterized by necroinflammatory activity with plasma cell infiltration might predict the development of this condition (183). In a pediatric series, the most common histological feature of de novo AIH was lobular hepatitis, often without interface necroinflammatory activity or prominent plasma cell infiltrates (184).

Awareness that treatment with prednisolone alone or in combination with azathioprine or MMF is successful in de novo AIH has led to excellent graft and patient survival (185). Akin to the recommended treatment for classical AIH, children should be given a starting dose of 1 to 2 mg/kg of prednisolone, without exceeding a daily dose of 60 mg, in combination with azathioprine (1–2 mg/kg); the steroids should then be tapered for 4 to 8 weeks, to reach a maintenance dose of 5 to 10 mg/day. In the absence of response, azathioprine should be replaced by MMF (185). The importance of maintenance therapy with steroids in de novo AIH was shown in a study comparing treatment with and without steroids. Whereas all steroid-untreated patients developed cirrhosis and either died or required retransplantation; none of the steroid-treated patients had progressive disease (186).

POSITION STATEMENTS

The diagnosis of autoimmune liver disease is based on presence of serum autoantibodies, elevated IgG, compatible liver histology, positive family history for autoimmune conditions, and exclusion of other causes of pediatric chronic liver disease. (9 strongly agree, 3 agree)

Percutaneous liver biopsy is the most important investigation and should be performed before starting treatment, unless there are contraindications, such as coagulopathy, ascites, or severe thrombocytopenia. The biopsy should then be deferred until these signs are improved on treatment. (11 strongly agree, 1 agree)

Typical histological features include chronic portal inflammation with mononuclear and plasma cells with interface activity, fibrosis or cirrhotic change. Various degrees of biliary changes and loss of hepatocytes could also be present. (10 strongly agree, 2 agree)

The first-line treatment is prednisolone/prednisone (2 mg · kg⁻¹ · day⁻¹, up to 60 mg/day), weaned down during 6 to 8 weeks to a maintenance dose of 5 to 7.5 mg/day, with monitoring of biochemical response alanine aminotransferase/aspartate aminotransferase (ALT/AST). (7 strongly agree, 5 agree)

Present experience with budenocide as the first-line treatment is limited and does not appear to offer clear clinical advantage over the standard treatment. (8 strongly agree, 4 agree)

In the presence of inadequate biochemical response to steroids after 4 to 6 weeks azathioprine should be added (0.5 mg/kg/d gradually increased to 2–2.5 mg · kg⁻¹ · day⁻¹). Routine measurement of TPMT activity and 6-TGN levels is not recommended. (1 strongly agree, 11 agree)

Additional second-line treatment options, if azathioprine fails to achieve normalization of liver function or is not tolerated, are mycophenolate, cyclosporine, and tacrolimus. Clear benefits of anti-CD20 antibodies, anti-TNF- α , and other biological treatments remain unproven at present time. (7 strongly agree, 5 agree)

Diagnosis of ASC requires cholangiography (magnetic resonance colangiopancreatography [MRCP], unless suspicion of distal biliary stricture, where endoscopic retrograde cholangiopancreatography [ERCP] is indicated). (11 strongly agree, 1 agree)

Parenchymal inflammation responds satisfactorily to standard immunosuppressive treatment with prednisolone/prednisone and azathioprine both in AIH and ASC, but the bile duct disease could progress in about 50% of the ASC cases, leading to end-stage liver disease requiring liver transplantation. (7 strongly agree, 5 agree)

Fecal calprotectin should be used as a screening test for inflammatory bowel disease, which is often associated with pediatric autoimmune liver disease, even in asymptomatic children. (11 strongly agree, 1 agree)

Colonoscopy should be considered for the patients with symptoms of IBD and the ones with clearly elevated fecal calprotectin. (11 strongly agree, 1 agree)

Maintenance immunosuppressive treatment should continue for at least 2 to 3 years. Complete biochemical and immunological response and repeated liver biopsy showing absence of inflammation increase the chances for potential withdrawal of immunosuppression. Gradual withdrawal of prednisolone/prednisone, followed by azathioprine, is recommended. The chances for successful withdrawal, however, remain between 20% and 40%. (6 strongly agree, 6 agree)

The patients after withdrawal of immunosuppression should continue to be monitored for AST/ALT/IgG/autoantibodies on a 3-monthly basis for at least 5 years. (8 strongly agree, 4 agree)

Liver transplantation is one option for patients with pediatric autoimmune liver disease who present with ALF or fail to respond to the medical treatment. Recurrence rates post-transplant, however, remain high, particularly for the patients with ASC. To reduce risks of recurrence, immunosuppression including azathioprine/MMF and small maintenance dose of steroids (up to 5 mg/day) is recommended. (8 strongly agree, 4 agree)

DISCLAIMER

ESPGHAN is not responsible for the practices of physicians and provides guidelines and position papers as indicators of best practice only. Diagnosis and treatment are at the discretion of physicians.

REFERENCES

- Mieli-Vergani G, Vergani D. Autoimmune liver disease: news and perspectives. *Transl Med UniSa* 2011;1:195–212.
- Roberts EA. Autoimmune hepatitis from the paediatric perspective. *Liver Int* 2011;31:1424–31.
- Mieli-Vergani G, Vergani D. Autoimmune liver diseases in children—what is different from adulthood? *Best Pract Res Clin Gastroenterol* 2011;25:783–95.
- Vajro P, Paoletta G. Autoimmune hepatitis: current knowledge. *Clin Res Hepatol Gastroenterol* 2012;36:284–6.
- Gossard AA, Lindor KD. Autoimmune hepatitis: a review. *J Gastroenterol* 2012;47:498–503.
- Della Corte C, Sartorelli MR, Comparcola D, et al. Autoimmune liver diseases. *Minerva Pediatr* 2012;64:595–606.
- Della Corte C, Sartorelli MR, Sindoni CD, et al. Autoimmune hepatitis in children: an overview of the disease focusing on current therapies. *Eur J Gastroenterol Hepatol* 2012;24:739–46.
- Zachou K, Muratori P, Koukoulis GK, et al. Review article: autoimmune hepatitis—current management and challenges. *Aliment Pharmacol Ther* 2013;38:887–913.
- Heneghan MA, Yeoman AD, Verma S, et al. Autoimmune hepatitis. *Lancet* 2013;382:1433–44.
- Mieli-Vergani G, Vergani D. Paediatric autoimmune liver disease. *Arch Dis Child* 2013;98:1012–7.
- Floreani A, Liberal R, Vergani D, et al. Autoimmune hepatitis: contrasts and comparisons in children and adults - a comprehensive review. *J Autoimmun* 2013;46:7–16.
- Hadzic N, Hierro L. Autoimmune liver disease: novelties in management. *Clin Res Hepatol Gastroenterol* 2014;38:273–6.
- Longhi MS, Mieli-Vergani G, Vergani D. Autoimmune hepatitis. *Curr Pediatr Rev* 2014;10:268–74.
- Moy L, Levine J. Autoimmune hepatitis: a classic autoimmune liver disease. *Curr Probl Pediatr Adolesc Health Care* 2014;44:341–6.
- Liberal R, Vergani D, Mieli-Vergani G. Update on autoimmune hepatitis. *J Clin Transl Hepatol* 2015;3:42–52.
- Wang Q, Yang F, Miao Q, et al. The clinical phenotypes of autoimmune hepatitis: a comprehensive review. *J Autoimmun* 2016;66:98–107.
- Liberal R, Vergani D, Mieli-Vergani G. Paediatric autoimmune liver disease. *Dig Dis* 2015;33(suppl 2):36–46.
- Waldenstrom JVS. Blutproteine und nahrungseiweiss. *Deutsch Z Verdau Stoffwechsellk* 1950;15:113–9.
- Joske RA, King WE. The L.E.-cell phenomenon in active chronic viral hepatitis. *Lancet* 1955;269:477–80.
- Mackay IR, Taft LI, Cowling DC. Lupoid hepatitis. *Lancet* 1956;ii:1323–6.
- Manns MP, Czaja AJ, Gorham JD, et al. Diagnosis and management of autoimmune hepatitis. *Hepatology* 2010;51:2193–213.
- European Association for the Study of the L. EASL Clinical Practice Guidelines: Autoimmune hepatitis. *J Hepatol* 2015;63:971–1004.
- Johnson PJ, McFarlane IG. Meeting report: International Autoimmune Hepatitis Group. *Hepatology* 1993;18:998–1005.
- Alvarez F, Berg PA, Bianchi FB, et al. International Autoimmune Hepatitis Group Report: review of criteria for diagnosis of autoimmune hepatitis. *J Hepatol* 1999;31:929–38.
- Hennes EM, Zeniya M, Czaja AJ, et al. Simplified criteria for the diagnosis of autoimmune hepatitis. *Hepatology* 2008;48:169–76.
- Ebbeson RL, Schreiber RA. Diagnosing autoimmune hepatitis in children: is the International Autoimmune Hepatitis Group scoring system useful? *Clin Gastroenterol Hepatol* 2004;2:935–40.
- Ferri PM, Ferreira AR, Miranda DM, et al. Diagnostic criteria for autoimmune hepatitis in children: a challenge for pediatric hepatologists. *World J Gastroenterol* 2012;18:4470–3.
- Mileti E, Rosenthal P, Peters MG. Validation and modification of simplified diagnostic criteria for autoimmune hepatitis in children. *Clin Gastroenterol Hepatol* 2012;10:417–21e1-2.
- Vergani D, Alvarez F, Bianchi FB, et al. Liver autoimmune serology: a consensus statement from the committee for autoimmune serology of the International Autoimmune Hepatitis Group. *J Hepatol* 2004;41:677–83.
- Hiejima E, Komatsu H, Sogo T, et al. Utility of simplified criteria for the diagnosis of autoimmune hepatitis in children. *J Pediatr Gastroenterol Nutr* 2011;52:470–3.
- Gregorio GV, Portmann B, Karani J, et al. Autoimmune hepatitis/sclerosing cholangitis overlap syndrome in childhood: a 16-year prospective study. *Hepatology* 2001;33:544–53.
- Czaja AJ, Carpenter HA. Autoimmune hepatitis. In: Macsween RNM, Burt AD, Portmann BC, eds. *Pathology of the Liver*. 4th Edition Churchill Livingstone; 2001:415–34.
- Miao Q, Bian Z, Tang R, et al. Emperipolesis mediated by CD8 T cells is a characteristic histopathologic feature of autoimmune hepatitis. *Clin Rev Allergy Immunol* 2015;48:226–35.
- de Boer YS, van Nieuwkerk CM, Witte BI, et al. Assessment of the histopathological key features in autoimmune hepatitis. *Histopathology* 2015;66:351–62.
- Kumari N, Kathuria R, Srivastava A, et al. Significance of histopathological features in differentiating autoimmune liver disease from nonautoimmune chronic liver disease in children. *Eur J Gastroenterol Hepatol* 2013;25:333–7.
- Tucker SM, Jonas MM, Perez-Atayde AR. Hyaline droplets in Kupffer cells: a novel diagnostic clue for autoimmune hepatitis. *Am J Surg Pathol* 2015;39:772–8.
- Tiniakos DG, Brain JG, Bury YA. Role of histopathology in autoimmune hepatitis. *Dig Dis* 2015;33(suppl 2):53–64.
- Stravitz RT, Lefkowitz JH, Fontana RJ, et al. Autoimmune acute liver failure: proposed clinical and histological criteria. *Hepatology* 2011;53:517–26.

39. Krawitt EL. Autoimmune hepatitis. *N Engl J Med* 2006;354:54–66.
40. Di Giorgio A, Bravi M, Bonanomi E, et al. Fulminant hepatic failure of autoimmune aetiology in children. *J Pediatr Gastroenterol Nutr* 2015;60:159–64.
41. Villalta D, Girolami E, Alessio MG, et al. Autoantibody profiling in a cohort of pediatric and adult patients with autoimmune hepatitis. *J Clin Lab Anal* 2016;30:41–6.
42. Gregorio GV, Portmann B, Mowat AP, et al. A 12-year-old girl with antimitochondrial antibody-positive autoimmune hepatitis. *J Hepatol* 1997;27:751–4.
43. Invernizzi P, Alessio MG, Smyk DS, et al. Autoimmune hepatitis type 2 associated with an unexpected and transient presence of primary biliary cirrhosis-specific antimitochondrial antibodies: a case study and review of the literature. *BMC Gastroenterol* 2012;12:92.
44. Saadah OI, Bokhary RY. Anti-mitochondrial antibody positive autoimmune hepatitis triggered by EBV infection in a young girl. *Arab J Gastroenterol* 2013;14:130–2.
45. Bailloud R, Bertin D, Roquelaure B, et al. Anti-mitochondrial-2 antibodies (anti-PDC-E2): a marker for autoimmune hepatitis of children? *Clin Res Hepatol Gastroenterol* 2012;36:e57–9.
46. Dinani AM, Fischer SE, Mosko J, et al. Patients with autoimmune hepatitis who have antimitochondrial antibodies need long-term follow-up to detect late development of primary biliary cirrhosis. *Clin Gastroenterol Hepatol* 2012;10:682–4.
47. Tan EM, Feltkamp TE, Smolen JS, et al. Range of antinuclear antibodies in “healthy” individuals. *Arthritis Rheum* 1997;40:1601–11.
48. Hilario MO, Len CA, Roja SC, et al. Frequency of antinuclear antibodies in healthy children and adolescents. *Clin Pediatr (Phila)* 2004;43:637–42.
49. Litwin CM, Binder SR. ANA testing in the presence of acute and chronic infections. *J Immunoassay Immunochem* 2016;37:439–52.
50. Bogdanos DP, Mieli-Vergani G, Vergani D. Autoantibodies and their antigens in autoimmune hepatitis. *Semin Liver Dis* 2009;29:241–53.
51. Liberal R, Mieli-Vergani G, Vergani D. Clinical significance of autoantibodies in autoimmune hepatitis. *J Autoimmun* 2013;46:17–24.
52. Lapiere P, Hajoui O, Homberg JC, et al. Formiminotransferase cyclodeaminase is an organ-specific autoantigen recognized by sera of patients with autoimmune hepatitis. *Gastroenterology* 1999;116:643–9.
53. Ma Y, Okamoto M, Thomas MG, et al. Antibodies to conformational epitopes of soluble liver antigen define a severe form of autoimmune liver disease. *Hepatology* 2002;35:658–64.
54. Palioura S, Sherrer RL, Steitz TA, et al. The human SepSecS-tRNA^{Sec} complex reveals the mechanism of selenocysteine formation. *Science* 2009;325:321–5.
55. Maggiore G, Socie G, Sciveres M, et al. Seronegative autoimmune hepatitis in children: Spectrum of disorders. *Dig Liver Dis* 2016;48:785–91.
56. Dehghani SM, Haghighat M, Imanieh MH, et al. Autoimmune hepatitis in children: experiences in a tertiary center. *Iran J Pediatr* 2013;23:302–8.
57. Hassan N, Siddiqui AR, Abbas Z, et al. Clinical profile and HLA typing of autoimmune hepatitis from Pakistan. *Hepat Mon* 2013;13:e13598.
58. Jimenez-Rivera C, Ling SC, Ahmed N, et al. Incidence and characteristics of autoimmune hepatitis. *Pediatrics* 2015;136:e1237–48.
59. Mieli-Vergani G, Vergani D. Budesonide for juvenile autoimmune hepatitis? Not yet. *J Pediatr* 2013;163:1246–8.
60. Gronbaek L, Vilstrup H, Jepsen P. Autoimmune hepatitis in Denmark: incidence, prevalence, prognosis, and causes of death. A nationwide registry-based cohort study. *J Hepatol* 2014;60:612–7.
61. Gregorio GV, Portmann B, Reid F, et al. Autoimmune hepatitis in childhood: a 20-year experience. *Hepatology* 1997;25:541–7.
62. Mieli-Vergani G, Heller S, Jara P, et al. Autoimmune hepatitis. *J Pediatr Gastroenterol Nutr* 2009;49:158–64.
63. Oettinger R, Brunnberg A, Gerner P, et al. Clinical features and biochemical data of Caucasian children at diagnosis of autoimmune hepatitis. *J Autoimmun* 2005;24:79–84.
64. Al-Chalabi T, Underhill JA, Portmann BC, et al. Impact of gender on the long-term outcome and survival of patients with autoimmune hepatitis. *J Hepatol* 2008;48:140–7.
65. Chai PF, Lee WS, Brown RM, et al. Childhood autoimmune liver disease: indications and outcome of liver transplantation. *J Pediatr Gastroenterol Nutr* 2010;50:295–302.
66. Deneau M, Book LS, Guthery SL, et al. Outcome after discontinuation of immunosuppression in children with autoimmune hepatitis: a population-based study. *J Pediatr* 2014;164:714–9.
67. Deneau M, Jensen MK, Holmen J, et al. Primary sclerosing cholangitis, autoimmune hepatitis, and overlap in Utah children: epidemiology and natural history. *Hepatology* 2013;58:1392–400.
68. Saadah OI, Smith AL, Hardikar W. Long-term outcome of autoimmune hepatitis in children. *J Gastroenterol Hepatol* 2001;16:1297–302.
69. Radhakrishnan KR, Alkhouri N, Worley S, et al. Autoimmune hepatitis in children—impact of cirrhosis at presentation on natural history and long-term outcome. *Dig Liver Dis* 2010;42:724–8.
70. Vitfell-Pedersen J, Jorgensen MH, Muller K, et al. Autoimmune hepatitis in children in Eastern Denmark. *J Pediatr Gastroenterol Nutr* 2012;55:376–9.
71. Amarapurkar D, Dharod M, Amarapurkar A. Autoimmune hepatitis in India: single tertiary referral centre experience. *Trop Gastroenterol* 2015;36:36–45.
72. Lee WS, Lum SH, Lim CB, et al. Characteristics and outcome of autoimmune liver disease in Asian children. *Hepatol Int* 2015;9:292–302.
73. Farid E, Isa HM, Al Nasef M, et al. Childhood autoimmune hepatitis in Bahrain: a tertiary center experience. *Iran J Immunol* 2015;12:141–8.
74. Low AS, Tan M, Garcia A, et al. Childhood autoimmune hepatitis in a paediatric unit of a tertiary care hospital. *Singapore Med J* 2014;55:648–51.
75. Nares-Cisneros J, Jaramillo-Rodriguez Y. Autoimmune hepatitis in children: progression of 20 cases in northern Mexico. *Rev Gastroenterol Mex* 2014;79:238–43.
76. Ramachandran J, Sajith KG, Pal S, et al. Clinicopathological profile and management of severe autoimmune hepatitis. *Trop Gastroenterol* 2014;35:25–31.
77. Roye-Green K, Willis R, Mc Morris N, et al. Autoimmune hepatitis in a Jamaican cohort spanning 40 years. *Hum Antibodies* 2013;22:87–93.
78. Abu Faddan NH, Abdel-Baky L, Aly SA, et al. Clinico-laboratory study on children with auto-immune hepatitis in Upper Egypt. *Arab J Gastroenterol* 2011;12:178–83.
79. Brissos J, Carrusca C, Correia M, et al. Autoimmune hepatitis: trust in transaminases. *BMJ Case Rep* 20142014.
80. Wong GW, Heneghan MA. Association of extrahepatic manifestations with autoimmune hepatitis. *Dig Dis* 2015;33(suppl 2):25–35.
81. Guo L, Zhou L, Zhang N, et al. Extrahepatic autoimmune diseases in patients with autoimmune liver diseases: a phenomenon neglected by gastroenterologists. *Gastroenterol Res Pract* 2017;2017:2376231.
82. Francavilla R, Castellaneta S, Davis T, et al. Serological markers of coeliac disease in children with autoimmune hepatitis. *Acta Endoscopica* 2001;3:281–2.
83. Najafi M, Sadjadei N, Eftekhari K, et al. Prevalence of celiac disease in children with autoimmune hepatitis and vice versa. *Iran J Pediatr* 2014;24:723–8.
84. Anania C, De Luca E, De Castro G, et al. Liver involvement in pediatric celiac disease. *World J Gastroenterol* 2015;21:5813–22.
85. Vajro P, Paolella G, Maggiore G, et al. Pediatric celiac disease, cryptogenic hypertransaminasemia, and autoimmune hepatitis. *J Pediatr Gastroenterol Nutr* 2013;56:663–70.
86. Nastasio S, Sciveres M, Riva S, et al. Celiac disease-associated autoimmune hepatitis in childhood: long-term response to treatment. *J Pediatr Gastroenterol Nutr* 2013;56:671–4.
87. Ahonen P, Myllarniemi S, Sipila I, et al. Clinical variation of autoimmune polyendocrinopathy-candidiasis-ectodermal dystrophy (APECED) in a series of 68 patients. *N Engl J Med* 1990;322:1829–36.
88. Meloni A, Willcox N, Meager A, et al. Autoimmune polyendocrine syndrome type 1: an extensive longitudinal study in Sardinian patients. *J Clin Endocrinol Metab* 2012;97:1114–24.
89. Ferre EM, Rose SR, Rosenzweig SD, et al. Redefined clinical features and diagnostic criteria in autoimmune polyendocrinopathy-candidiasis-ectodermal dystrophy. *JCI Insight* 20161(13).

90. Milner JD, Vogel TP, Forbes L, et al. Early-onset lymphoproliferation and autoimmunity caused by germline STAT3 gain-of-function mutations. *Blood* 2015;125:591–9.
91. Lopez SI, Ciocca M, Oleastro M, et al. Autoimmune hepatitis type 2 in a child with IPEX syndrome. *J Pediatr Gastroenterol Nutr* 2011;53:690–3.
92. Grimbacher B, Warnatz K, Yong PF, et al. The crossroads of autoimmunity and immunodeficiency: Lessons from polygenic traits and monogenic defects. *J Allergy Clin Immunol* 2016;137:3–17quiz 8.
93. Ferreira AR, Roquete ML, Toppa NH, et al. Effect of treatment of hepatic histopathology in children and adolescents with autoimmune hepatitis. *J Pediatr Gastroenterol Nutr* 2008;46:65–70.
94. Sogo T, Fujisawa T, Inui A, et al. Intravenous methylprednisolone pulse therapy for children with autoimmune hepatitis. *Hepatol Res* 2006;34:187–92.
95. Al-Chalabi T, Heneghan MA. Remission in autoimmune hepatitis: what is it, and can it ever be achieved? *Am J Gastroenterol* 2007;102:1013–5.
96. Kerkar N, Annunziato RA, Foley L, et al. Prospective analysis of nonadherence in autoimmune hepatitis: a common problem. *J Pediatr Gastroenterol Nutr* 2006;43:629–34.
97. Samaroo B, Samyn M, Buchanan C, et al. Long-term daily oral treatment with prednisolone in children with autoimmune liver disease does not affect final adult height. *Hepatology* 2006;44:438A.
98. Alvarez F. Autoimmune hepatitis and primary sclerosing cholangitis. *Clin Liver Dis* 2006;10:89–107.
99. Chang MH, Hadzic D, Rouassant SH, et al. Acute and chronic hepatitis: working group report of the second World Congress of Pediatric Gastroenterology, Hepatology, and Nutrition. *J Pediatr Gastroenterol Nutr* 2004;39(suppl 2):S584–8.
100. Gulati R, Radhakrishnan KR, Hupertz V, et al. Health-related quality of life in children with autoimmune liver disease. *J Pediatr Gastroenterol Nutr* 2013;57:444–50.
101. Czaja AJ, Bianchi FB, Carpenter HA, et al. Treatment challenges and investigational opportunities in autoimmune hepatitis. *Hepatology* 2005;41:207–15.
102. Pniewska A, Sobolewska-Pilarczyk M, Pawlowska M. Evaluation of the effectiveness of treatment with prednisone and azathioprine of autoimmune hepatitis in children. *Prz Gastroenterol* 2016;11:18–23.
103. Heneghan MA, Allan ML, Bornstein JD, et al. Utility of thiopurine methyltransferase genotyping and phenotyping, and measurement of azathioprine metabolites in the management of patients with autoimmune hepatitis. *J Hepatol* 2006;45:584–91.
104. Rumbo C, Emerick KM, Emre S, et al. Azathioprine metabolite measurements in the treatment of autoimmune hepatitis in pediatric patients: a preliminary report. *J Pediatr Gastroenterol Nutr* 2002;35:391–8.
105. Sheik MA, Sundaram SS, Capocelli KE, et al. Outcomes in pediatric autoimmune hepatitis and significance of azathioprine metabolites. *J Pediatr Gastroenterol Nutr* 2017;65:80–5.
106. Mohammad S. Budesonide as first-line therapy for non-cirrhotic autoimmune hepatitis in children: a decision analysis. *Scand J Gastroenterol* 2016;51:753–62.
107. Manns MP, Woynarowski M, Kreisel W, et al. Budesonide induces remission more effectively than prednisone in a controlled trial of patients with autoimmune hepatitis. *Gastroenterology* 2010;139:1198–206.
108. Woynarowski M, Nemeth A, Baruch Y, et al. Budesonide versus prednisone with azathioprine for the treatment of autoimmune hepatitis in children and adolescents. *J Pediatr* 2013;163:1347–53.
109. Alvarez F, Ciocca M, Canero-Velasco C, et al. Short-term cyclosporine induces a remission of autoimmune hepatitis in children. *J Hepatol* 1999;30:222–7.
110. Cuarterolo M, Ciocca M, Velasco CC, et al. Follow-up of children with autoimmune hepatitis treated with cyclosporine. *J Pediatr Gastroenterol Nutr* 2006;43:635–9.
111. Franulovic OZ, Rajacic N, Lesar T, et al. Cyclosporine induced biochemical remission in childhood autoimmune hepatitis. *Coll Antropol* 2012;36:973–9.
112. Marlaka JR, Papadogiannakis N, Fischler B, et al. Tacrolimus without or with the addition of conventional immunosuppressive treatment in juvenile autoimmune hepatitis. *Acta Paediatr* 2012;101:993–9.
113. Aw MM, Dhawan A, Samyn M, et al. Mycophenolate mofetil as rescue treatment for autoimmune liver disease in children: a 5-year follow-up. *J Hepatol* 2009;51:156–60.
114. Zizzo AN, Valentino PL, Shah PS, et al. Second-line agents in pediatric patients with autoimmune hepatitis: a systematic review and meta-analysis. *J Pediatr Gastroenterol Nutr* 2009;65:6–15.
115. D'Agostino D, Costaguta A, Alvarez F. Successful treatment of refractory autoimmune hepatitis with rituximab. *Pediatrics* 2013;132:e526–30.
116. Kavcic M, Fisher BT, Seif AE, et al. Leveraging administrative data to monitor rituximab use in 2875 patients at 42 freestanding children's hospitals across the United States. *J Pediatr* 2013;162:1252–8.
117. Weiler-Normann C, Schramm C, Quaas A, et al. Infliximab as a rescue treatment in difficult-to-treat autoimmune hepatitis. *J Hepatol* 2013;58:529–34.
118. Rajanayagam J, Lewindon PJ. Infliximab as rescue therapy in paediatric autoimmune hepatitis. *J Hepatol* 2013;59:908–9.
119. Rodrigues S, Lopes S, Magro F, et al. Autoimmune hepatitis and anti-tumor necrosis factor alpha therapy: a single center report of 8 cases. *World J Gastroenterol* 2015;21:7584–8.
120. Mostamand S, Schroeder S, Schenkein J, et al. Infliximab-associated immunomediated hepatitis in children with inflammatory bowel disease. *J Pediatr Gastroenterol Nutr* 2016;63:94–7.
121. Mieli-Vergani G, Vergani D. Autoimmune hepatitis. *Nat Rev Gastroenterol Hepatol* 2011;8:320–9.
122. Battaglia M, Stabilini A, Roncarolo MG. Rapamycin selectively expands CD4+CD25+FoxP3+ regulatory T cells. *Blood* 2005;105:4743–8.
123. Kurowski J, Melin-Aldana H, Bass L, et al. Sirolimus as rescue therapy in pediatric autoimmune hepatitis. *J Pediatr Gastroenterol Nutr* 2014;58:e4–6.
124. De Boer YS, Liberal R, Vergani D, et al. International Autoimmune Hepatitis Group. Real world management of juvenile autoimmune liver disease. *J Hepatol* 2017;66(S550).
125. Liberal R, de Boer YS, Andrade RJ, et al. Expert clinical management of autoimmune hepatitis in the real world. *Aliment Pharmacol Ther* 2017;45:723–32.
126. Ichai P, Duclos-Vallee JC, Guettier C, et al. Usefulness of corticosteroids for the treatment of severe and fulminant forms of autoimmune hepatitis. *Liver Transpl* 2007;13:996–1003.
127. Narkewicz MR, Horslen S, Belle SH, et al. Prevalence and significance of autoantibodies in children with acute liver failure. *J Pediatr Gastroenterol Nutr* 2017;64:210–7.
128. van Gerven NM, Verwer BJ, Witte BI, et al. Relapse is almost universal after withdrawal of immunosuppressive medication in patients with autoimmune hepatitis in remission. *J Hepatol* 2013;58:141–7.
129. Mieli-Vergani G, Vergani D. Sclerosing cholangitis in children and adolescents. *Clin Liver Dis* 2016;20:99–111.
130. Ziol M, Barbu V, Rosmorduc O, et al. ABCB4 heterozygous gene mutations associated with fibrosing cholestatic liver disease in adults. *Gastroenterology* 2008;135:131–41.
131. Rojas CP, Bodicharla R, Campuzano-Zuluaga G, et al. Autoimmune hepatitis and primary sclerosing cholangitis in children and adolescents. *Fetal Pediatr Pathol* 2014;33:202–9.
132. Rodrigues AT, Liu PM, Fagundes ED, et al. Clinical characteristics and prognosis in children and adolescents with autoimmune hepatitis and overlap syndrome. *J Pediatr Gastroenterol Nutr* 2016;63:76–81.
133. Mitchell SA, Bansi DS, Hunt N, et al. A preliminary trial of high-dose ursodeoxycholic acid in primary sclerosing cholangitis. *Gastroenterology* 2001;121:900–7.
134. Lindor KD, Kowdley KV, Luketic VA, et al. High-dose ursodeoxycholic acid for the treatment of primary sclerosing cholangitis. *Hepatology* 2009;50:808–14.
135. Deneau MR, El-Matary W, Valentino PL, et al. The natural history of primary sclerosing cholangitis in 781 children: A multicenter, international collaboration. *Hepatology* 2017;66:518–27.
136. Debray D, Pariente D, Urvoas E, et al. Sclerosing cholangitis in children. *J Pediatr* 1994;124:49–56.
137. Smolka V, Karaskova E, Tkachyk O, et al. Long-term follow-up of children and adolescents with primary sclerosing cholangitis and autoimmune sclerosing cholangitis. *Hepatobiliary Pancreat Dis Int* 2016;15:412–8.

138. Tenca A, Farkkila M, Arola J, et al. Clinical course and prognosis of pediatric-onset primary sclerosing cholangitis. *United European Gastroenterol J* 2016;4:562–9.
139. Wilschanski M, Chait P, Wade JA, et al. Primary sclerosing cholangitis in 32 children: clinical, laboratory, and radiographic features, with survival analysis. *Hepatology* 1995;22:1415–22.
140. Feldstein AE, Perrault J, El-Youssif M, et al. Primary sclerosing cholangitis in children: a long-term follow-up study. *Hepatology* 2003;38:210–7.
141. Miloh T, Arnon R, Shneider B, et al. A retrospective single-center review of primary sclerosing cholangitis in children. *Clin Gastroenterol Hepatol* 2009;7:239–45.
142. Valentino PL, Wiggins S, Harney S, et al. The natural history of primary sclerosing cholangitis in children: a large single-center longitudinal cohort study. *J Pediatr Gastroenterol Nutr* 2016;63:603–9.
143. Bjarnason I, Hayee B, Pavlidis P, et al. Contrasting pattern of chronic inflammatory bowel disease in primary and autoimmune sclerosing cholangitis. *EBioMedicine* 2015;2:1523–7.
144. Martin SR, Alvarez F, Anand R, et al. Outcomes in children who underwent transplantation for autoimmune hepatitis. *Liver Transpl* 2011;17:393–401.
145. Bahar RJ, Yanni GS, Martin MG, et al. Orthotopic liver transplantation for autoimmune hepatitis and cryptogenic chronic hepatitis in children. *Transplantation* 2001;72:829–33.
146. Vergani D, Mieli-Vergani G. Autoimmunity after liver transplantation. *Hepatology* 2002;36:271–6.
147. Miloh T, Anand R, Yin W, et al. Pediatric liver transplantation for primary sclerosing cholangitis. *Liver Transpl* 2011;17:925–33.
148. Squires RH, Ng V, Romero R, et al. Evaluation of the pediatric patient for liver transplantation: 2014 practice guideline by the American Association for the Study of Liver Diseases, American Society of Transplantation and the North American Society for Pediatric Gastroenterology, Hepatology and Nutrition. *Hepatology* 2014;60:362–98.
149. Scalori A, Heneghan MA, Hadzic D, et al. Outcome and survival in childhood onset autoimmune sclerosing cholangitis and autoimmune hepatitis: a 13-year follow up study. *Hepatology* 2007;46(Suppl): 555A.
150. Liberal R, Zen Y, Mieli-Vergani G, et al. Liver transplantation and autoimmune liver diseases. *Liver Transpl* 2013;19:1065–77.
151. Edmunds C, Ekong UD. Autoimmune liver disease post-liver transplantation: a summary and proposed areas for future research. *Transplantation* 2016;100:515–24.
152. Kerker N, Yanni G. 'De novo' and 'recurrent' autoimmune hepatitis after liver transplantation: a comprehensive review. *J Autoimmun* 2016;66:17–24.
153. Liberal R, Vergani D, Mieli-Vergani G. Recurrence of autoimmune liver disease and inflammatory bowel disease after pediatric liver transplantation. *Liver Transpl* 2016;22:1275–83.
154. Montano-Loza AJ, Bhanji RA, Wasilenko S, et al. Systematic review: recurrent autoimmune liver diseases after liver transplantation. *Aliment Pharmacol Ther* 2017;45:485–500.
155. Puustinen L, Boyd S, Arkkila P, et al. Histologic surveillance after liver transplantation due to autoimmune hepatitis. *Clin Transplant* 2017;31.
156. Ayata G, Gordon FD, Lewis WD, et al. Liver transplantation for autoimmune hepatitis: a long-term pathologic study. *Hepatology* 2000;32:185–92.
157. Birnbaum AH, Benkov KJ, Pittman NS, et al. Recurrence of autoimmune hepatitis in children after liver transplantation. *J Pediatr Gastroenterol Nutr* 1997;25:20–5.
158. Banff Working G, Demetris AJ, Adeyi O, et al. Liver biopsy interpretation for causes of late liver allograft dysfunction. *Hepatology* 2006;44:489–501.
159. Wright HL, Bou-Abboud CF, Hassanein T, et al. Disease recurrence and rejection following liver transplantation for autoimmune chronic active liver disease. *Transplantation* 1992;53:136–9.
160. Gonzalez-Koch A, Czaja AJ, Carpenter HA, et al. Recurrent autoimmune hepatitis after orthotopic liver transplantation. *Liver Transpl* 2001;7:302–10.
161. Prados E, Cuervas-Mons V, de la Mata M, et al. Outcome of autoimmune hepatitis after liver transplantation. *Transplantation* 1998;66: 1645–50.
162. Sempoux C, Horsmans Y, Lerut J, et al. Acute lobular hepatitis as the first manifestation of recurrent autoimmune hepatitis after orthotopic liver transplantation. *Liver* 1997;17:311–5.
163. Czaja AJ. The immunoreactive propensity of autoimmune hepatitis: is it corticosteroid-dependent after liver transplantation? *Liver Transpl Surg* 1999;5:460–3.
164. Montano-Loza AJ, Mason AL, Ma M, et al. Risk factors for recurrence of autoimmune hepatitis after liver transplantation. *Liver Transpl* 2009;15:1254–61.
165. Reich DJ, Fiel I, Guarrera JV, et al. Liver transplantation for autoimmune hepatitis. *Hepatology* 2000;32 (4 pt 1):693–700.
166. Gotz G, Neuhaus R, Bechstein WO, et al. Recurrence of autoimmune hepatitis after liver transplantation. *Transplant Proc* 1999;31:430–1.
167. Gautam M, Cheruvattath R, Balan V. Recurrence of autoimmune liver disease after liver transplantation: a systematic review. *Liver Transpl* 2006;12:1813–24.
168. Hurtova M, Duclos-Vallee JC, Johanet C, et al. Successful tacrolimus therapy for a severe recurrence of type 1 autoimmune hepatitis in a liver graft recipient. *Liver Transpl* 2001;7:556–8.
169. Jossen J, Annunziato R, Kim HS, et al. Liver transplantation for children with primary sclerosing cholangitis and autoimmune hepatitis: UNOS database analysis. *J Pediatr Gastroenterol Nutr* 2017; 64:e83–7.
170. Duclos-Vallee JC, Sebah M, Rifai K, et al. A 10 year follow up study of patients transplanted for autoimmune hepatitis: histological recurrence precedes clinical and biochemical recurrence. *Gut* 2003;52:893–7.
171. Venkat VL, Ranganathan S, Mazariegos GV, et al. Recurrence of primary sclerosing cholangitis in pediatric liver transplant recipients. *Liver Transpl* 2014;20:679–86.
172. Graziadei IW, Wiesner RH, Batts KP, et al. Recurrence of primary sclerosing cholangitis following liver transplantation. *Hepatology* 1999;29:1050–6.
173. Graziadei IW. Recurrence of primary sclerosing cholangitis after liver transplantation. *Liver Transpl* 2002;8:575–81.
174. Alabraba E, Nightingale P, Gunson B, et al. A re-evaluation of the risk factors for the recurrence of primary sclerosing cholangitis in liver allografts. *Liver Transpl* 2009;15:330–40.
175. Carbone M, Neuberger J. Liver transplantation in PBC and PSC: indications and disease recurrence. *Clin Res Hepatol Gastroenterol* 2011;35:446–54.
176. Chen CY, Ho MC, Wu JF, et al. Development of autoantibodies after pediatric liver transplantation. *Pediatr Transplant* 2013;17:144–8.
177. Kerker N, Hadzic N, Davies ET, et al. De-novo autoimmune hepatitis after liver transplantation. *Lancet* 1998;351:409–13.
178. Hernandez HM, Kovarik P, Whittington PF, et al. Autoimmune hepatitis as a late complication of liver transplantation. *J Pediatr Gastroenterol Nutr* 2001;32:131–6.
179. Gupta P, Hart J, Millis JM, et al. De novo hepatitis with autoimmune antibodies and atypical histology: a rare cause of late graft dysfunction after pediatric liver transplantation. *Transplantation* 2001;71:664–8.
180. Andries S, Casamayou L, Sempoux C, et al. Posttransplant immune hepatitis in pediatric liver transplant recipients: incidence and maintenance therapy with azathioprine. *Transplantation* 2001;72:267–72.
181. Venick RS, McDiarmid SV, Farmer DG, et al. Rejection and steroid dependence: unique risk factors in the development of pediatric posttransplant de novo autoimmune hepatitis. *Am J Transplant* 2007;7:955–63.
182. Miyagawa-Hayashino A, Haga H, Egawa H, et al. Outcome and risk factors of de novo autoimmune hepatitis in living-donor liver transplantation. *Transplantation* 2004;78:128–35.
183. Sebah M, Castillo-Rama M, Azoulay D, et al. Histologic findings predictive of a diagnosis of de novo autoimmune hepatitis after liver transplantation in adults. *Transplantation* 2013;96:670–8.
184. Pongpaibul A, Venick RS, McDiarmid SV, et al. Histopathology of de novo autoimmune hepatitis. *Liver Transpl* 2012;18:811–8.
185. Liberal R, Longhi MS, Grant CR, et al. Autoimmune hepatitis after liver transplantation. *Clin Gastroenterol Hepatol* 2012;10:346–53.
186. Salcedo M, Vaquero J, Banares R, et al. Response to steroids in de novo autoimmune hepatitis after liver transplantation. *Hepatology* 2002; 35:349–56.