

Liver Biopsy in Children: Position Paper of the ESPGHAN Hepatology Committee

*Antal Dezsófi, †Ulrich Baumann, ‡Anil Dhawan, §Ozlem Durmaz, ||Björn Fischler, ¶Nedim Hadzic, #Loreto Hierro, **Florence Lacaille, ††Valérie A. McLin, ‡‡Valerio Nobili, §§Piotr Socha, ||||Pietro Vajro, and ¶¶Alexander S. Knisely

ABSTRACT

Liver biopsy (LB) is still the criterion standard procedure for obtaining liver tissue for histopathological examination and a valuable tool in the diagnosis, prognosis, and management of many parenchymal liver diseases. The aim of this position paper is to summarise the present practice of paediatric LB and make recommendations about its performance. Although histological evaluation of the liver is important in assessing prognosis and exploring treatment, noninvasive techniques (ie, imaging, laboratory markers) may replace use of liver histology. The indications for LB are changing as present knowledge of aetiologies, pathomechanism, and therapeutic options in paediatric liver disease is evolving. Adult and paediatric literature was reviewed to assess the existing clinical practice of LB with focus on the technique, indications, risk of complications, and contraindications in paediatrics. This position paper presents types of LB, indications, complications, contraindications, and an essential checklist for paediatric LB.

Key Words: children, complications, contraindications, indications, liver biopsy, paediatric

(*JPGN* 2015;60: 408–420)

Received September 8, 2014; accepted November 5, 2014.

From the *First Department of Pediatrics, Semmelweis University, Budapest, Hungary, the †Paediatric Gastroenterology and Hepatology, Hannover Medical School, Hannover, Germany, the ‡Kings College London School of Medicine at Kings College Hospital, London, UK, the §Istanbul Medical Faculty, Istanbul University, Istanbul, Turkey, the ||Department of Pediatrics, CLINTEC, Karolinska University Hospital, Stockholm, Sweden, the ¶Paediatric Centre for Hepatology, Gastroenterology and Nutrition, King's College Hospital, London, UK, the #Paediatric Hepatology Service, Hospital Infantil Universitario "La Paz," Madrid, Spain, the **Necker-Enfants Malades Hospital, Paris, France, the ††Paediatric Gastroenterology Unit, Department of Pediatrics, University Hospitals Geneva, Switzerland, the ‡‡Hepatometabolic Unit, Bambino Gesù Children's Hospital, Rome, Italy, the §§Department of Gastroenterology, Hepatology and Nutritional Disturbances, Children's Memorial Health Institute, Warsaw, Poland, the ||||Department of Medicine and Surgery, University of Salerno, Salerno, Italy, and the ¶¶Institute of Liver Studies/King's College Hospital, London, UK.

Address correspondence and reprint requests to Antal Dezsófi, 1083, Bókay János utca 53, Budapest, Hungary (e-mail: dezsofi.antal@med.semmelweis-univ.hu).

This article has been developed as a Journal CME Activity by NASPGHAN. Visit <http://www.naspghan.org/content/59/en/Continuing-Medical-Education-CME> to view instructions, documentation, and the complete necessary steps to receive CME credit for reading this article.

The authors report no conflicts of interest.

Copyright © 2015 by European Society for Pediatric Gastroenterology, Hepatology, and Nutrition and North American Society for Pediatric Gastroenterology, Hepatology, and Nutrition
DOI: 10.1097/MPG.0000000000000632

INTRODUCTION

The role of liver biopsy (LB) in the management of patients with acute and chronic liver diseases has significantly evolved in recent years. The decision to biopsy a patient for diagnosis, staging, and prognostic evaluation has become more individualised, and standard indications have been challenged as information increasingly has become available by routes other than LB.

Percutaneous LB using the Menghini technique has been established as simple, reliable, and minimally invasive since its introduction into clinical practice in the late 1950s (1,2). Its safety record is acceptable and various histopathological techniques, including transmission electron microscopy (TEM) and immunohistochemistry, have enhanced LB interpretation and clinical relevance. The key to its usefulness is collaboration between clinicians and histopathologists, whose close interaction dramatically increases the value of LB. In the era of genomic medicine, additional noninvasive methods, including mutational analyses, advanced radiological methods, and sophisticated biochemical assays, however, have begun to compete seriously with conventional clinical investigations such as LB. Simpler clinical tests avoid logistical complications, hospital admissions, and periprocedural risks associated with LB. Nonetheless, emerging opportunities permit LB to offer otherwise unavailable information on metabolic/liver conditions in which phenotypes overlap, with immunohistochemical detection of biochemical and genetic disorders or assessment of immune-mediated complications after liver transplantation.

Aim

The aim of this review is to assess the role of LB in the present dynamic clinical environment, referring to evidence in the limited published paediatric literature and—when not available—also to evidence in adult patients. When paediatric data are not unanimous, a consensus was developed.

METHODOLOGY

Literature was screened by a PubMed search of English and non-English-language articles using the following terms: children, LB, needles, indications, complications, contraindications, monitoring of patients, safety issues. Relevant articles were selected from search result lists. Published abstracts from European and American gastroenterology and hepatology conferences during the last 30 years also were reviewed.

INDICATIONS FOR LB

LB can be performed in native or in transplanted liver. The purpose of LB can be diagnostic; it can be prognostic when

diagnosis is known and severity needs to be assessed, and it can be to monitor disease progression or response to treatment.

LB for Diagnostic Purposes

Neonatal Cholestasis

In the newborn or extremely young infant, the principal primary liver diseases substantially overlap phenotypically with one another and with secondary liver dysfunction (effects of prematurity, asphyxia, or sepsis): the clinical signs of neonatal cholestasis can be identical (hypocholic stools, dark urine, jaundice, hypoglycaemia). Some forms of neonatal cholestasis can be identified biochemically and genetically, or by imaging studies. Others require LB.

Although LB at this age may aid in diagnosis, interpretation requires familiarity with various pitfalls. Liver microanatomy differs from that in older infants, toddlers, and older children or adults. Interlobular bile ducts are smaller in premature or extremely young infants and in the liver periphery (which biopsy preferentially samples); to find copper-associated protein and iron is normal till age 4 months; and haemopoietic elements may persist until age 6 months. Multinucleated hepatocytes with abundant cytoplasm (syncytial giant cells) develop nonspecifically following various insults. Histopathological hallmarks may be not visible early (as in α_1 -antitrypsin storage disorder [A1ASD], Alagille syndrome [AGS], or Niemann-Pick disease type C). Immunohistochemical staining or TEM may be required in these cases.

Typical in biliary atresia (BA) are acholic stools, firm livers, and abnormal values for biochemical markers of hepatobiliary injury ("biomarkers"). Success of portoenterostomy depends in part on age at surgery—the younger the better—and some believe that LB or endoscopic retrograde cholangiopancreatography only delays definitive treatment. Clinical findings attain 80% to 90% accuracy in the diagnosis of BA (3). Histopathological evaluation permits diagnosis of BA in 96% of adequate LB specimens: core specimens are "adequate" if they measure at least 2.0 cm long and 0.2 mm wide, or contain at least 10 portal tracts; wedge specimens are adequate if they contain at least 6 complete portal tracts independent of the liver capsule (4). Typical in BA are prominent ductular reaction, bile plugs within portal-tract bile ducts (not periportal neocholangioles), and portal-tract expansion by oedema and fibrosis. Findings may, however, be similar in parenteral alimentation, protease inhibitor type Z A1ASD, or cystic fibrosis. Typical findings may also be missing before ages 4 to 6 weeks (4–6). LB for microbiologic culture after portoenterostomy can be valuable in assessing recurrent or antibiotic-resistant cholangitis.

Progressive Familial Intrahepatic Cholestasis

The clinical diagnosis of progressive familial intrahepatic cholestasis (PFIC) is based on jaundice, elevated serum concentrations of primary bile acids with low/normal serum γ -glutamyl transpeptidase (GGT) activity (familial intrahepatic cholestasis [FIC1] deficiency or bile salt export pump [BSEP] deficiency, normal-GGT PFIC) or with high serum GGT activity (multidrug resistance protein 3 [MDR3] deficiency), absence of dysmorphism, and, as coordinated behaviour emerges, evidence of pruritus. Histopathological findings in the liver are useful in supporting the diagnosis. In severe FIC1 deficiency (*ATP8B1* mutation, chromosome 18), small, tidily arrayed hepatocytes and pallid intracanalicular bile are seen. In severe BSEP deficiency (*ABCB11* mutation, chromosome 2) bile is khaki-coloured rather than greyish. Bile pigment accumulates in hepatocytes and in canaliculi, with hepatocellular giant cell change and necrosis. In neither are portal-

tract changes prominent; bile plugs are not seen within portal tracts, and ductular reaction is sparse, with hypoplasia (not absence) of principal bile duct radicals. Immunostaining for BSEP (negative in 75% to 90% of BSEP-deficient patients, positive in FIC1 deficiency) and for ectoenzymes (negative in FIC1 deficiency, positive in BSEP deficiency) such as GGT, carcinoembryonic antigen (CD66), and alanyl aminopeptidase (CD13) can assist diagnosis. TEM of LB material primarily fixed for ultrastructural study can be useful; coarsely and loosely granular canalicular contents suggest FIC1 deficiency (7). BSEP deficiency and primary bile acid synthesis disorders cannot be distinguished histopathologically without immunostaining (8,9). In most infants with clinically manifest BSEP deficiency, however, deficiency is absolute, with absent BSEP expression, whereas in primary bile acid synthesis disorders canaliculi mark normally for BSEP.

Partial biliary diversion (PBD) has been widely used to ameliorate symptoms in normal GGT PFIC when ursodeoxycholic acid treatment fails (10,11). Because cirrhosis makes symptom relief with PBD less likely, LB is essential in clinical decision making (12). Coordinated immunohistological and genetic evaluation may help assess prognosis after PBD; in *ABCB11* disease, for example, if BSEP is expressed, response is more likely than if no BSEP is demonstrable.

Severe deficiency of MDR3, encoded by *ABCB4*, can present in infancy. LB in infants and young children finds portal tract fibrosis with mixed inflammation and, unlike normal GGT PFIC, ductular proliferation, suggesting cholangiopathy (13–15). Immunostaining for MDR3 can be useful in diagnosis if MDR3 is not expressed along canalicular margins (15).

MDR3 permits entry into bile of phospholipid, which maintains cholesterol in solution. Cholesterol clefts (residua of precipitated cholesterol crystals) in bile duct lumina may signal *ABCB4* disease, as may hepatocellular copper deposits unusually abundant for cholangiopathy (16,17).

Alagille Syndrome

AGS is largely diagnosed using clinical and extrahepatic criteria, but an important feature—paucity of interlobular bile ducts (PILBDs)—can only be documented histologically. If bile flow from the lobule is deficient, new bile ducts at the periphery of the biliary tree may be hypoplastic, but not absent. LB samples subcapsular liver with newly formed portal tracts and potentially hypoplastic bile ducts. If bile duct radicals are not highlighted by immunostaining, PILBD may be misdiagnosed. In AGS, PILBD may not be present in young infants; even after age 1 year 25% of AGS LB specimens do not show PILBD (18). LB timing is crucial.

PBD does not alter liver disease progression in AGS, although it may relieve pruritus (19). No known clinical or histopathological parameter predicts response to PBD. Histopathological and clinical findings before and after PBD in AGS await correlation.

α_1 -Antitrypsin Storage Disorder

Only 10% to 15% of individuals deficient in circulating α_1 -antitrypsin and of protease inhibitor type Z phenotype develop liver disease. Features in infancy include intralobular and, rarely, portal-tract cholestasis, ductular reaction, bile duct hypoplasia (misreported as paucity), mild periportal steatosis, and portal fibrosis, that aside from steatosis is a near phenocopy of BA. Because A1ASD can be confirmed by isoelectric protein focussing or *SERPINA1* mutation analysis, LB is not required; indeed, diagnostic features (granular cytoplasmic bodies that after diastase digestion take the periodic acid-Schiff stain) may not be apparent in

early infancy, and immunostaining for α_1 -antitrypsin may be required to demonstrate them. Whether histopathological or clinical findings more helpfully reflect liver disease severity and medium- to long-term prognosis is unclear (20). Bridging septa, severe fibrosis, and ductular reaction at presentation may suggest likely progression to requiring liver transplantation (21).

Acute Liver Failure

Aetiologies of acute liver failure (ALF) remain indeterminate in approximately 50% of children who require liver transplantation (22–24). The role of LB in ALF is limited and questionable. Multisystem impairment and severe coagulopathy make percutaneous LB high-risk, and transjugular (TJ) LB in children requires general anaesthesia, contraindicated unless the patient is already ventilated. Although some conditions causing ALF may be diagnosed histopathologically (25), histopathological study of LB specimens or explanted livers does not increase the diagnostic yield in children with ALF (26), and histopathological diagnosis does not alter immediate management.

TJ LB may assist in diagnosis occasionally in sub-ALF or in autoimmune hepatitis (AIH) or Wilson disease (WD) when other test results are unclear (27,28). Necrosis and regeneration often are, however, patchy and sampling error is likely.

Bridging fibrosis suggests chronic disease, potentially treatable (AIH, WD). But histopathological distinction among acute, subacute, and chronic injury is difficult, owing to sampling bias and overlap among conditions and phases. Such diagnoses generally can be reached less invasively. Apart from chronic liver disease, bridging fibrosis can be seen during recovery from acute injury (acetaminophen or other), in quiescent or treated AIH, and in sub-ALF.

Cryptogenic Hypertransaminasaemia

Although history, examination, imaging, and biomarker and molecular testing clarify aetiology in most persistent cryptogenic hypertransaminasaemia, LB remains standard because it allows for fibrosis staging and grading of inflammation, influencing treatment and prognostication. Noninvasive fibrosis assessment (elastography, extracellular-matrix biomarker determinations) will probably soon affect LB use in this regard. In adults (and children (29)), when cause of biomarker abnormalities is initially unclear, non-alcoholic fatty liver disease (NAFLD) is to be considered. Magnetic resonance imaging of steatosis, bringing detection below ultrasonography's 30% limit, may also affect LB use in suspected NAFLD. For some conditions (noncirrhotic portal hypertension, nodular regenerative hyperplasia, hepatoportal sclerosis), diagnosis will probably continue to require LB.

Lysosomal Acid Lipase Deficiency (Wolman Disease, Cholesteryl Ester Storage Disease)

Deficiency of lysosomal acid lipase (LAL), involved in intracellular hydrolysis of cholesteryl esters and triglycerides, underlies these disorders (30). LAL activity can be assayed in lymphocytes and cultured skin fibroblasts (31). LB is not indicated unless enzymatic testing is unavailable or inconclusive. LAL inhibitor Lalstatat 2 assays, using dried blood spots (32), may expand noninvasive testing. LB, when done, finds hepatocellular microvesicular steatosis and foamy, enlarged Kupffer cells (30). Cholesterol clefts strongly suggest LAL deficiency. LB may be prognostically useful (fibrosis, portal hypertension).

NAFLD

LB is required for definitive diagnosis of NAFLD but is not proposed in screening. LB is indicated to exclude other diseases, if advanced disease is suspected, before pharmacological or surgical treatment, and in clinical research trials (33).

AIH

LB should be performed at presentation in all of the patients with suspected AIH to confirm diagnosis, to grade inflammation, and to stage fibrosis. Coagulopathy and thrombocytopenia may preclude LB until empiric immunosuppression ameliorates hypo-coagulability. When considering withdrawal of immunosuppression after at least 1 year of complete biomarker remission, LB is mandatory to document absence of inflammation (34).

LB in Assessment of Known Liver Disease

Wilson Disease

As no histopathological feature of WD is specific—steatosis, inflammation, fibrosis, and cirrhosis all are seen in other conditions—histopathological findings in the liver are not diagnostic criteria in WD. Liver copper content, however, is included in WD diagnostic scoring (35), and when WD is a consideration LB is usually indicated, with histopathological study ancillary to liver copper measurement. Concentrations $>250 \mu\text{g/g}$ (dry tissue) are considered diagnostic for WD in adolescents or adults; however, increased hepatic copper content suggests rather than demonstrates WD, because chronic cholestasis also may increase hepatic copper stores (36). Whether LB is indicated in patients with 2 known *ATP7B* mutations remains debatable.

Drug-Induced Liver Injury

Drug-induced liver injury (DILI) is a diagnosis of exclusion, established on the basis of clinical, biochemical, and histopathological data (history, interval between exposure and liver injury, and the suspect agent's known toxicity (37)). Histological findings in DILI include cholestasis, hepatitis, fibrosis, and inflammation, often with plasma cell infiltrates, suggesting immune-mediated injury (38). When a predominant feature—cholestasis, inflammatory injury—can be matched with known drug effect, LB may help identify which among several drug exposures is aetiologic (39). LB can distinguish acute and chronic injury (fibrosis), and may allow assessment of preexisting disease. In DILI in children, data are scarce, although histopathological findings seem similar to those in adults (40). A recent study in children did not include LB as a criterion for diagnosis of DILI (41). LB may be indicated when the diagnosis of DILI is ambiguous, when withdrawal of the suspect drug is clinically unacceptable, or when the patient requires repeated courses of the drug.

Sclerosing Cholangitis

Sclerosing cholangitis is usually a disease of large- and middle-sized bile ducts, identifiable on imaging study. These ducts are not generally sampled at LB. LB can, however, detect disease restricted to small ducts. Typical are periductal “onion-skin” fibrosis, copper deposits, and upstream consequences of biliary obstruction (ductular reaction, portal tract oedema, and fibrosis) (42).

LB is necessary to diagnose overlap syndrome (coexistent AIH and sclerosing cholangitis, with biomarker evidence of autoimmunity and biomarker or imaging study evidence of cholangiopathy) and, if chronic changes are seen, can be useful in prognostication.

Congenital Disorders of Glycosylation

Congenital disorders of glycosylation are diagnosed using biomarkers; LB is not required. Portal tract fibrosis and typical congenital hepatic fibrosis (CHF) are described in congenital disorders of glycosylation type 1 (43). The only consequences are portal hypertension and cholangitis, as in CHF. To stage fibrosis in LB materials may guide screening for portal hypertension (43). Slighter hepatic changes may be observed in a subset of cases with prevalent or exclusive hepatic presentation (44).

CHF and Ciliopathies (Fibrocystic Hepatorenal Diseases)

LB is not indicated to diagnose CHF associated with renal disease (polycystic kidney disease, nephronophthisis) when findings are typical (large and hard liver, normal range biomarker values). LB can be of use in ciliopathies if the liver phenotype is unclear and if to characterise it would alter management.

LB features are not of prognostic value in CHF; prognosis depends on severity of portal hypertension and incidence of cholangitis. LB may be helpful for bacteriological culture in recurrent or resistant cholangitis. LB can also be useful in assessing liver disease associated with other ciliopathies (eg, Jeune; Senior-Loken; Joubert; cerebellar vermis hypo/aplasia, oligophrenia, ataxia, ocular coloboma, and hepatic fibrosis syndromes) (45).

Hepatitis B Virus Infection

LB can be useful in chronic hepatitis B virus infection with prolonged immune activation state, that is, when hepatitis B virus surface and E antigens and elevated transaminase activity are repeatedly demonstrable. Marked inflammation (necroinflammatory activity) suggests likely benefit from treatment (interferon or antivirals). Staging of fibrosis also can modify treatment (46,47).

Hepatitis C Virus Infection

Hepatitis C virus (HCV) infection in childhood usually runs a slow course. By the end of adolescence, a few patients (approximately 1.8% (48)), however, develop cirrhosis. Patients infected with HCV genotype 2 or 3, for which a successful treatment regimen is available, may be offered antiviral therapy without biopsy. At present standard treatment of infection with HCV genotype 1 or 4 yields no >50% success. LB in patients infected with HCV of these genotypes can be useful; if fibrosis is mild, expectant management (awaiting better regimens) is justifiable (48,49). Although duration of infection is the major risk factor for progression of fibrosis, rates of progression in individuals remain unpredictable (50).

Cytomegalovirus Infection

Biomarker abnormalities often warrant LB in liver transplant recipients. LB can help to distinguish primary or reactivated cytomegalovirus infection from various forms of rejection. Lobular hepatitis with occasional apoptotic hepatocytes is usual; pathognomonic “owl-eye” cytopathic effects are rarely seen. Immunostaining can be helpful (51).

Epstein-Barr Virus Infection

LB can be of some value in liver transplant recipients with Epstein-Barr virus (EBV) primary infection and biomarker

abnormalities. Predominantly lobular hepatitis is characteristic (52). Immunohistochemical or *in situ* hybridisation studies can confirm EBV involvement (53). Liver-localised EBV-related post-transplant lymphoproliferative disease may occasionally be diagnosed at LB as well (54).

Liver Tumours

Liver tumours are rare in children. Hepatoblastoma is the most frequently seen malignancy. Depending on levels of alpha-fetoprotein, histology is often necessary for diagnosis; histopathological findings contribute substantially to prognosis. Hepatocellular carcinoma (HCC) is the second most common liver malignancy in childhood. Only 20% to 35% of children with HCC have underlying liver disease (55). Biopsy of HCC carries a substantial risk of needle track seeding (1.6%–5%) and should only be considered if diagnosis cannot be made with imaging studies (56).

Liver Transplantation

As noted above, biomarker abnormalities often warrant LB in liver transplant recipients. LB findings constitute the criterion standard in diagnosing acute cellular or chronic ductopaenic rejection. LB may assist in diagnosis of some infections (demonstration of granulomata or cytomegalovirus inclusions) and in assessing the graft in patients with EBV viraemia.

Debate continues regarding “protocol LB,” that is, LB every 5 or 10 years after transplantation even when no disorder is suspected, more often performed in paediatric than in adult practice. This may be because abnormal histopathological findings are frequent in children after liver transplantation (57), whereas in adults not infected with HCV only changes of little impact are found (58). Although protocol LB can provide valuable information about inflammatory changes (*de novo* AIH) or fibrosis that may affect immunosuppressive treatment (59–61), its benefits must be weighed against potential complications. Strategies to reduce nephrotoxicity by weaning immunosuppression and to assess immune tolerance have underscored the value of protocol LB in patient management (62). Indications include the following:

1. Biomarker evidence of graft dysfunction when imaging study and microbiological investigations suggest no cause
2. Suspected acute cellular rejection
3. Suspected chronic ductopaenic rejection
4. Suspected recurrent disease
5. Staging and grading of graft function (regular follow-up LB, ischaemia-associated bile duct lesions, obstructive cholangiopathies)
6. Bacteriological culture for recurrent or resistant cholangitis

APPROACH TO LB

LB technique is often chosen on the basis of the risk profile in the individual patient, but the choice also depends on personal experience and practice of the clinician. LB is most commonly performed percutaneously. If this approach is not feasible, the TJ or laparoscopic approach can be chosen, as can laparotomy.

Percutaneous LB

“Blind LB” is done without contemporaneous imaging study (predominantly ultrasonographic) guidance in determining the puncture site. The classic manner is the percussion-guided mid-clavicular intercostal approach. For exclusion of anatomical variation, all of the patients should have undergone an abdominal

ultrasound at some stage before a blind LB. This is the simplest and least invasive method of obtaining a core of the liver tissue from the right lobe for histopathological examination. It is considered for presumed diffuse hepatic parenchymal disease. “Ultrasound-assisted LB,” a variation in which a hepatologist examines the proposed biopsy site ultrasonographically immediately before LB, can improve the yield of liver tissue and enhance safety (63).

“Ultrasound-guided or computerised tomography-guided LB” is chosen either when a focal lesion must be sampled or when somatic features, including obesity, obscure anatomical landmarks used for percutaneous LB. After segmental liver graft transplantation owing to the specific anatomic situation, blind LB is not recommended; ultrasound-guided or -assisted LB is the investigation of choice.

Ultrasonographic guidance was shown to be associated with decreased rates of hospitalisation among adult patients. The final decision about whether to use ultrasonography routinely should not be based on economic factors (64). Many physicians prefer image-guided biopsy for both diffuse parenchymal disease and focal lesions (65).

Plugged (Plugged-Tract) LB

Plugged LB is a modification of percutaneous LB in which collagen, thrombin, or a comparable material is injected as the needle is withdrawn.

TJ LB

TJ LB is performed by interventional radiologists in high-risk patients (with severe liver disease and coagulopathy, pancytopenia, or ascites) and in patients with an underlying contraindication to percutaneous LB, such as haematological conditions. Potential disadvantages of TJ LB include that tissue samples are small and may be fragmented, both limiting histopathological diagnostic value. Advances in biopsy needle design and wider experience in technique, with multiple cores now obtainable, have improved both the quality of samples and the diagnostic yield (66–68).

LB at Laparoscopy, Mini-Laparotomy, and Laparotomy

Wedge LB under direct observation is recommended only in exceptional settings because the peripheral tissue sampled is less representative of the liver, particularly for staging of fibrosis, than is the standard needle biopsy specimen. The laparoscopic approach may, however, be performed to obtain samples of liver tissue in specific circumstances. Possible benefits of laparoscopy are increased specimen size and immediate control of possible intra-procedural haemorrhage (63,69) and the selection of biopsy site on inspection of the liver (70). A disadvantage is the use of electrocautery, which can substantially impede histopathological interpretation. Cold-knife excision is thus preferable for specimen retrieval, with haemostasis by electrocoagulation afterward. One possibility is needle LB under laparoscopic vision, which allows deeper biopsy sampling and efficient bleeding control as well. Conditions to be considered for laparoscopic LB are as follows:

1. Increased risk of bleeding (69)
2. Ascites of unknown aetiology
3. Evaluation of abdominal mass
4. Failure of previous percutaneous LB (71)
5. Requirement for a large biopsy sample for enzymatic analysis, that is, in suspected metabolic conditions

Contraindications to laparoscopic LB (72) may be classified as absolute (severe cardiopulmonary failure, intestinal obstruction, bacterial peritonitis) and relative (morbid obesity, large ventral hernia).

LB DEVICES

Two types of needles are generally used to perform LB: “cutting needles” (Tru-Cut, Vim-Silverman and Temno) and “suction needles” (Menghini, Klatskin, Jamshidi) (72,73). These 2 types use different methods for sampling tissue. They are available in different diameters. The type and gauge optimal for percutaneous LB have been the subject of several studies (73). The diameter used for LB in chronic hepatopathies usually varies between 1.2 and 1.8 mm (73) or 1.6 and 1.8 mm (74), with length varying from 7 to 9 cm (74) according to patient age. The advantages of smaller suction needles with regard to safety should be weighed against the disadvantages of the smaller LB specimen with regard to adequacy. A recent study supports the routine use of 16-G rather than 18-G biopsy needles for routine ultrasound-guided LB (75).

Specimens from Tru-Cut needles may give more information about hepatic architecture. To take >1 liver core at biopsy may increase not only diagnostic yield, but also morbidity (76). When a blind percutaneous LB is performed, taking 2 specimens may improve diagnostic yield, but the numbers of minor complications may increase when >3 consecutive passes are done (76,77).

LIVER SPECIMEN HANDLING

A fragment of liver tissue only 1 mm in diameter can suffice for diagnosis in some disorders (ultrastructural study); in most situations, however, an assessment of features throughout several lobules or portal tracts is required (as with architectural features that reflect abnormal perfusion). No definite rules for LB size, thus, can be given independent of clinical context. Light microscopy of routinely stained sections of tissue fixed in formalin and processed into paraffin will provide a preliminary diagnosis. Discussion between histopathologist and clinician of the findings and of the diagnosis advanced should direct further studies.

In selected cases one may consider snap-freezing a portion of any LB specimen and to hold the frozen tissue at -80°C if special investigations are required. An ultrastructural study of the sample could provide additional diagnostic information, as in, for example, suspected storage disorders or suspected *ATP8B1* disease, to store a sample in glutaraldehyde also is recommended. The frozen aliquot can be thawed in solutions that impede breakdown of RNA or DNA if molecular analysis is required; it can be analysed for metal contents, various products of intermediary metabolism, or exogenous toxins. It also can be thawed in glutaraldehyde if ultrastructural study is indicated. Biopsy specimens for quantitative copper determination should be placed unfixed on a moist piece of filter paper or directly in a copper-free container.

Distribution of an LB sample for routine (formalin) fixation, snap-freezing, and special study protocols should take place at bedside, immediately after LB. A core 20-mm long and 1.8 mm in diameter is required for optimal “routine” histopathological interpretation. In summary, a liver sample should be stored in formalin for histopathological investigation with, if possible, a portion snap frozen and held for additional special studies.

TYPES OF ANAESTHESIA

All efforts should be made to reduce anxiety and pain, and to ensure safety of the LB. Depending on local practice, general anaesthesia or sedation may be used to ensure this. The additional use of a long-acting local anaesthetic at the site of biopsy is recommended.

COMPLICATIONS OF LB

Complications of LB (Tables 1 and 2) (63,79–84) are usually considered to be “major” or “minor.” We consider “minor” complications to include pain, subcapsular bleeding that does not require transfusion or prolonged hospitalisation, infection, minor bile leak or haemobilia, and arteriovenous fistula. “Major” complications include bleeding, including haemobilia, that requires transfusion, surgery, or intensive care management; pneumothorax or haemothorax; and death (78).

Timing of Complications

According to adult studies, 60% of complications occur in the first 2 hours after LB and 96% within the first 24 hours (79–81). Fatal complications occur within 6 hours of LB, except for late, unpredictable complications (82,83). In a paediatric study examining the feasibility of outpatient LB, bleeding complications were reported in 1% of children, with clinical symptoms occurring within 4 hours of LB (84).

Bleeding

The incidence of bleeding following percutaneous LB is difficult to assess. Clinically significant bleeding events, that is, with haemodynamic repercussions or warranting transfusion, occur in approximately 1 of 2500 to 10,000 LB in adults with diffuse parenchymal disease (85–88). Bleeding was reported in 2.8% of 469 paediatric LB procedures, and increased with malignancies or after bone marrow transplant (89). A 15% incidence of bleeding after LB in children with oncological disease also was reported (90). In a recent study (275 LB, 190 in children), the risk of bleeding was significantly increased in patients with a focal lesion and in patients receiving low-molecular-weight heparin (91). Furthermore, routine ultrasonography after LB revealed clinically unsuspected haemorrhage at a rate of 2.6% (7/266) (91). Patients with ALF were at increased risk for major bleeding. Of note was that use of low-dose aspirin in the 5 days before LB did not increase the risk of bleeding (91).

Pain

In adult LB, pain is the most widely reported complication, affecting as many as 84% of patients (92). Pain typically occurs at 2 sites: at the LB site and at the right shoulder (“referred” pain). In a study focused precisely on analysing pain after LB in 54 adults, 9 reported LB site pain, 14 right shoulder pain, and 24 pain at both sites (92). No such data exist in children, but our general clinical

TABLE 1. Incidence of minor and major complications

Complications (minor and major)	Incidence (adult and child)
Pain	84% adults (79)
Bleeding	0%–18% adults (reviewed in (63)), 2.8% children (80)
Arteriovenous fistula	No data
Pneumothorax/haemothorax	0.2% (80)
Organ perforation	0.07%–1.25% (81,82)
Biliary leak/haemobilia	0.6% children (80)
Infection	12.5% in choledochojejunostomy (83)
Death	0%–0.4% adults (reviewed in (63)), 0.6% children (80)

TABLE 2. Risk factors for complications (see references)

Risk factor for minor or major complications
Low-molecular-weight heparin use (79)
Focal lesion (79)
Acute liver failure (79)
Infants age <3 months (79,80)
Massive ascites (81)
Thrombocytopenia (82)
Previous malignancy or bone marrow transplantation (81,82)
Chronic renal failure (83)
Biliary tract dilatation (84)

impression is that pain after LB is mild, well tolerated, and controlled by minor analgesia. Obviously, should pain persist or worsen, urgent ultrasonography is warranted to identify any of the complications discussed here.

Arteriovenous Fistula

Descriptions of arteriovenous fistula secondary to LB are few, are usually presented as case reports, and are rare in children (93–95). The outcome was fatal in 1 child who had undergone liver transplantation (95). How soon arteriovenous fistula may develop after LB is unclear, as are the risk factors leading to this complication. This diagnosis should be suspected in the presence of an abdominal bruit or in a patient who has recently undergone LB and who presents with signs of acute portal hypertension, abdominal distension, or liver failure. Management is by emergency closure via either image-guided intervention or surgery (96,97).

Pneumothorax and Haemothorax

Pneumothorax and haemothorax are possible complications of percutaneous LB. Only 1 case of pneumothorax has been reported in a paediatric study (89) ($n = 1$, 0.2%). In a meta-analysis of studies in adults, incidence was 0.05%; this seemed significantly reduced when ultrasonographic guidance was used (98).

Organ Perforation

The incidence of hollow viscus perforation following percutaneous LB in adults varies between 0.07% (99) and 1.25% (100), and in children, it is unknown. It should, however, be suspected when the course after LB is abnormal or is marked by substantial pain. Management can be surgical or expectant. Chilaiditi syndrome (colonic interposition between the liver and the diaphragm) should be excluded before performing blind LB.

Bile Leak and Haemobilia

In a large meta-analysis of adult TJ LB, the incidence of biliary fistula was 0.01% and that of haemobilia was 0.04% (98). In a cohort of 1500 adults undergoing percutaneous LB, only 1 case of biliary peritonitis occurred; it was fatal (101). Bile leaks have been reported after 3 paediatric LB procedures (0.6%) (89). Embolisation is currently preferred for the management of uncontrolled haemobilia (101–103).

Infection

Infection, either at the site of puncture or systemic, is a possible complication of percutaneous LB, but its incidence in

adults is extremely low (104). Nevertheless, and of relevance to paediatric practice, the incidence of sepsis after LB is higher in adult liver transplant recipients who underwent choledochojejunostomy than in recipients with direct bile duct to bile duct anastomosis (104). Although comparable data do not exist for children, most transplanted children have a Roux-en-Y loop-enteric anastomosis. Antibiotic prophylaxis at the time of LB may be appropriate in this high-risk subgroup to decrease the frequency of infectious complications (104).

Death

In large adult cohorts, the risk of death following LB is reported as 1:10,000. For TJ LB, the rate is a little higher (0.09%), but this may reflect the use of TJ LB in more severely ill patients (98). In children, 3 deaths have been reported in 469 LB (0.6%), all occurring in patients with a history of malignancy or haematological disease (89). Two recent studies have reported no deaths (91,105). Two deaths before the implementation of TJ LB have been reported for oncological disease patients (90). Our review suggests that haemato-oncology patients are at increased risk for major bleeding and death after LB. To consider these patients as at high risk seems justified, as do specific cautionary measures (see below) to limit complications, in particular bleeding. TJ LB may be safer than percutaneous or open LB.

Complications in TJ LB or Plugged-Tract LB in Adults and Children

It is widely accepted that TJ LB or plugged-tract LB is preferable to percutaneous LB in adults and children with coagulopathy or ascites (69,106). One study in adults, however, suggests that the presence of ascites does not increase the risk of major or minor complications in patients undergoing image-guided percutaneous LB (107). A study analysing an in-house protocol of TJ LB in adults and plugged-tract LB in children reported that plugged-tract LB in children with ascites was generally safe and was not associated with a frequency of complications greater than that seen with TJ LB (108). The total complication rate (in adults and children) was 0.9%, which was significantly lower than previously reported (98,109). In a study specifically of TJ LB in children and adults, the complication rate was 2.4% and the mortality rate was 0.25% (68). Of those patients with major bleeding complications, half ($n = 200$) had a significant coagulopathy, the most frequent indication for TJ LB. On the contrary, plugged-tract LB in adult patients with coagulopathy and thrombocytopenia is reportedly safe (110).

Needle Size, Needle Diameter, and Number of Passes

Increases in calibre of LB trocar and in number of passes are widely thought to predispose to complications, including bleeding. Data from adult studies and in animal models are, however, ambiguous, permitting no firm conclusions (85,88,111).

In conclusion, data are scant on complications following paediatric percutaneous LB, TJ LB, or plugged LB. Small infants and patients with cancer or haematological disease appear at increased risk for bleeding, as may be patients with AGS (112). Studies in adults suggest that children with a hepatobiliary-enteric anastomosis may be at increased risk for sepsis after LB. No convincing evidence exists that ultrasonographic guidance either before or during LB reduces complication rates. Plugged LB or laparoscopic LB may offer an option safer than TJ LB in high-risk patients.

Special Populations

1. Patients with end-stage chronic renal disease
Adults with chronic renal failure are generally regarded as at greater risk for bleeding after LB, owing to platelet dysfunction. This assumption, however, remains unproven and the benefit of 1-desamino-8-D-arginine, vasopressin in improving this dysfunction remains unclear (113,114). Because paediatric evidence is lacking, we feel that children with end-stage chronic renal disease in whom bleeding times do not improve with vasopressin administration should be considered for plugged-tract LB where available, preferably following a session of renal replacement therapy (haemodialysis or haemofiltration), to minimise bleeding risks.
2. Patients with AGS or with arthrogyrosis-renal dysfunction-cholestasis (ARC) syndrome
Patients with AGS-associated cholestatic liver disease do not always need LB because the diagnosis can be established by other means. Furthermore, patients with AGS may have an increased bleeding tendency, and 1 death in AGS because of bleeding after LB has been reported in 1 paediatric cohort (112). As in AGS, extrahepatic findings in ARC syndrome can suggest the diagnosis. These include arthrogyrosis, in particular ichthyosis, Fanconi-like renal tubulopathy, normal range serum GGT activity despite conjugated hyperbilirubinaemia, and, on blood film, increased platelet size. Platelet dysfunction in ARC syndrome has contributed to severe haemorrhage after both renal biopsy and LB (115).
3. Young infants
Infants <3 months of age may be more likely to have sedation-related complications than are children in the general paediatric population. In 1 study examining the outcome of 66 LB in infants, the complication rate attributed to sedation (sedation-related respiratory difficulty) was 10%, compared with an older cohort in which it was 2.6% (89,116). It is important to note the absence of major complications, and that all resolved with minimal clinical measures. Patients with a pronounced drop in haematocrit responded to transfusion, and patients with respiratory depression responded to naloxone. The rate and distribution of complications not associated with sedation did not differ from those in other age groups. Thus, many centres perform LB under local anaesthesia only in this age group.
4. Low-birth-weight babies
With children in this subcategory, the operator must be more cautious regarding sedation and general fitness for LB and anaesthesiological support should be considered.

CONTRAINDICATIONS TO PERCUTANEOUS LB IN CHILDREN

Abnormal Coagulation and/or Thrombocytopenia

All centres at which LB is performed will define ranges for coagulation parameters that either preclude LB or warrant administration of blood products. Correlations between such coagulation-parameter values and bleeding risk are, however, weak, and many reported episodes of severe haemorrhage after LB have occurred in patients with normal coagulation factor levels. Furthermore, because advanced liver disease affects production of both procoagulants and anticoagulants, net effects on bleeding risk are often difficult to predict. More comprehensive coagulation assays that evaluate several aspects of haemostasis are promising, but no such method used before LB has yet proven practical to predict that complications will not arise (117,118)

Prothrombin-complex values, measured as international normalized ratio (INR), are often used to identify patients at risk for bleeding. INR values were, however, originally standardised for patients on oral anticoagulant therapy. Similar standardisation is required for patients with liver disease, as recently suggested (119), but an “INR liver” is not yet routinely available. With all of these caveats in mind, we propose the following cutoff levels:

INR: A value of 1.5 or higher, usually regarded as a contraindication to LB, may require that fresh-frozen plasma (FFP) or factor concentrate, such as recombinant factor VII, be given before LB (120,121).

Platelets: A count of $60 \times 10^9/L$ or lower may represent an indication for platelet transfusion immediately before LB (4).

The above recommendations do not consider platelet function, which can best be evaluated by bleeding time determination (122). Furthermore, increased fibrinolysis is common in advanced liver disease. Supplementation should be considered if the plasma concentration of fibrinogen is <1.0 g/L. Finally, patients with abnormally prolonged activated partial thromboplastin times need to be evaluated for milder forms of haemophilia and for von Willebrand disease before LB is done. To detect patients at risk, a thorough enquiry into personal and family histories of bruising and mucosal bleeding is mandatory.

Ascites

LB in a patient with voluminous ascites should be avoided for several reasons. The risk of haemodynamic complications after LB is increased, particularly in smaller children, because of bleeding and/or biopsy site leakage of fluid, which could lead to peritonitis. Without imaging study guidance, the safety and diagnostic yield of LB are often poorer, because the correct position of the liver is more difficult to ascertain.

Specific Patient Categories

When deciding on LB, factors for increased risk need to be identified and taken into account. Thus, haemato-oncological patients, in particular after haematopoietic stem cell transplantation, are at increased risk (123). Percutaneous LB in patients during sickle cell crisis should be avoided if possible, considering the disproportionately high risk of fatal complications (124). In case of suspected haemophagocytic lymphohistiocytosis LB should also definitely be avoided.

To minimise risk of complications, ultrasonography should be performed before LB to identify contraindications such as ascites, biliary dilatation, peliosis, or haemangioma and anatomic variation such as abdominal *situs inversus*. How often hepatic haemangiomas occur in the general paediatric population is unknown, but the prevalence in adults is 1.5% (125). Abdominal *situs inversus* is estimated to occur in 1:10,000 to 1:25,000 individuals (126).

RECOMMENDED PROTOCOL AND CHECKLIST

Most paediatric recommendations adhere to the recent extensively reviewed adult AASLD guidelines (63). This section highlights major and/or specific issues.

Before LB

1. Informed consent
Informed consent should be obtained before LB according to national and local regulations. Consent should be documented in the family's native language (76), with, if necessary, the presence of an interpreter. Parents should be educated about LB

(procedure, risks, and benefits) and the nature of liver disease in their child (63).

2. Sedation/anaesthesia
(see section “Approach to LB”)
3. Haematological testing
Before percutaneous LB all of the patients should undergo these laboratory investigations:
 - a. full blood count
 - b. determination of indices of hepatobiliary injury, including total and direct serum bilirubin, alanine aminotransferase, aspartate aminotransferase, alkaline phosphatase, GGT, prothrombin complex time (PT)/INR, activated partial thromboplastin time, and fibrinogen. Bleeding time determination could be considered if platelet dysfunction is suspected. In most cases PT/INR and platelet count should be checked within the 24 hours previous to the LB (63,74).
If the PT is prolonged by 4 seconds or more, equivalent to INR >1.5 , then strategies to ameliorate coagulopathy should be deployed (74,76,127,128). If patients show abnormalities of the coagulation cascade, support with vitamin K and with transfusions of FFP or platelets may be required. Vitamin K is useful in most cases but should be given parenterally and at least 6 hours before LB. If this is insufficient, FFP given immediately before LB at a dose of 12 to 15 mL/kg body weight may correct PT/INR values (74,76). Alternatively, recombinant factor VII is effective (120).
No data on a safe INR threshold are published. Abnormal PT/INR needs to be balanced against other risk factors and the overall clinical benefit of LB. The panel overall suggests that an INR value >1.5 warrants factor substitution or LB by TJ or laparoscopic approach.
The platelet count threshold for a safe percutaneous LB is relatively controversial and depends on local expertise. Some data indicate that with a platelet count as low as 60,000 (63,76,129), 75,000 (130), or 80,000/mm³ (127), percutaneous LB can be performed with no increase in complication rate provided all other coagulation parameters are normal.
Platelet infusion before percutaneous LB has been used widely in thrombocytopenic patients. Studies showing its efficacy are, however, lacking, particularly in patients with hypersplenism owing to liver disease who may also have other disorders of coagulation (76,127).
Patients with hereditary bleeding disorders (factor VIII or XI deficiency, von Willebrand disease) can undergo LB following supplementation with the deficient species, provided clinical indication is robust. The risk–benefit ratio must be considered with caution (63).
No drugs interfering with platelet count or coagulation factors (eg, aspirin, warfarin) should be used (for details see below). Low-dose aspirin, frequently given after liver transplantation, is generally not stopped before LB.
4. Ultrasonography before LB
See next section
5. Therapeutic management before LB
Patients undergoing LB should observe some therapeutic recommendations:
 - a. Antiplatelet therapy (except low-dose aspirin given after liver transplantation) should be discontinued at least 7 to 10 days before LB and must be restarted 48 to 72 hours after LB.
 - b. Warfarin administration should be discontinued 5 days before LB and may be restarted 24 hours after LB; administration of heparin and related products should be interrupted 12 to 24 hours before LB (63).

- c. In patients with valvular heart disease (according to cardiologic guidelines), documented bacteraemia, or chronic cholangiopathy after liver transplantation, peri-procedural intravenous antibiotic prophylaxis should be administered (127).
- d. If a history of hypoglycaemia exists, an intravenous infusion of glucose should be started to maintain blood glucose levels during fasting before LB.

LB: THE PROCEDURE

1. Patients should fast for 4 hours before LB; this may vary depending on age, clinical condition, and local policy. Vital signs, including heart rate, respiratory rate, arterial blood pressure, and core body temperature, should be assessed 1 hour before LB (63,74,76).
2. The patient should lie supine in a comfortable position with the right arm placed behind the head. After sedation/anaesthesia, long-acting local anaesthetic (ie, bupivacaine 0.5%) should be topically infiltrated of (63,73,74) into skin and soft tissue at the region of maximal dullness at percussion between the 7th and 9th intercostal space or in a more appropriate site if bedside ultrasonography is performed (127).
3. The region of the needle entry must be cleaned with an alcohol-based solution and draped with sterile cloths (63).
4. The needle must be introduced in the right mid-axillary line above the rib; if ultrasonography is not available and the operator uses an intercostal approach, the needle should be introduced 1 intercostal space below the superior margin of liver dullness. If the operator uses a subcostal approach, the needle should be introduced in the midclavicular line below the costal margin (63,74,76,127) (Fig. 1).
5. LB with ultrasonographic guidance reduces complication rates, as it permits directing biopsy away from gallbladder, vascular structures, colon, and lung (63,76). Real-time ultrasonographic guidance helps in finding the most suitable site to perform LB and allows reducing the number of passes into the liver. In children, ultrasonography provides guidance better than computerised tomography because ionising radiation exposure is avoided, with real-time imaging, greater versatility and portability, and lower costs (131). Furthermore, liver parenchyma could be identified without extreme ventilatory movements (63). It should be emphasised that after liver transplantation, using only anatomical landmarks to guide the site of biopsy is insufficient; image-guided LB (eg, ultrasound) is recommended.

6. The LB specimen should be handled according to agreed local protocol modified to accommodate diagnostic considerations in the individual patient (see above).

After LB

1. Immediately after LB the needle entry site should be firmly compressed to procure haemostasis. The patient should fast for approximately 2 hours after LB and vital signs (blood pressure, heart rate, respiratory rate) should be monitored closely for at least 6 hours after LB (127). Oxygen saturation monitoring also is advised (74,76).
2. The patient should remain in bed for a minimum of 1 hour after LB or until vital signs are stable.
3. If bleeding is suspected, a full blood count may be requested. The interpretation of this needs to take into consideration that a detectable decrease in the haemoglobin value needs some time to develop. Abdominal ultrasonography at bedside may also be required for the assessment of bleeding complications. Laparotomy or image-guided embolisation may be required for life-threatening bleeding (127). If pneumothorax is suspected, posteroanterior and lateral chest roentgenograms may be useful.
4. Determinations of serum haemoglobin concentration and haematocrit should be considered only if clinically justified.
5. The patient should be observed for at least 6 hours for signs or symptoms that suggest complications, such as severe pain, shoulder pain (in older children), irritability (in infants), bleeding, discharge at LB site, difficulty in breathing, pallor, and fever (132).
6. LB is often performed in an outpatient setting, but many units prefer 1 overnight stay.
7. Contact sports should be avoided during the first week after LB.

TRAINING REQUIREMENTS

At present no well-established evidence-based guidelines exist for training and experience required to qualify a person to perform LB. Although the number of biopsies that must be performed to become proficient is unknown, the American Association for the Study of Liver Disease recommended that operators perform at least 40 biopsies under supervision (63).

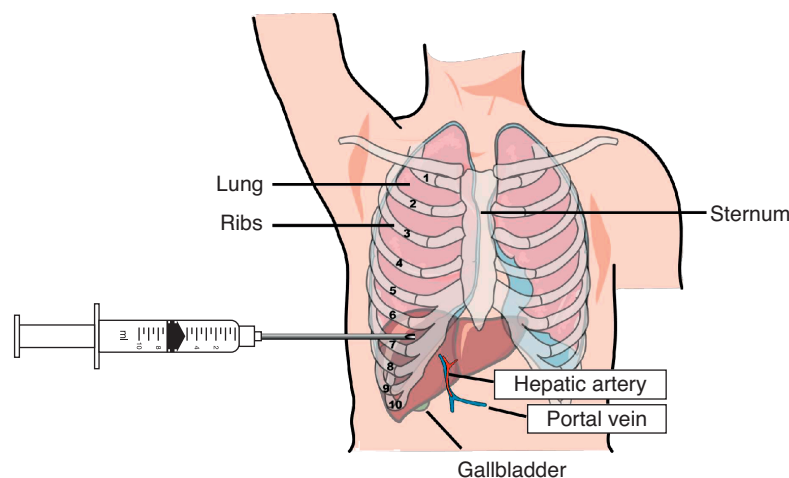


FIGURE 1. The approach to percutaneous LB. LB = liver biopsy.

In 1999 the North American Society for Pediatric Gastroenterology and Nutrition published Guidelines for Training in Pediatric Gastroenterology, which states that for competence in percutaneous LB the trainee should independently perform at least 20 biopsies, half in infants and children <3 years of age (133). The American Gastroenterology Association, in “Training the Gastroenterologist for the Future,” recommends that trainees acquire competence by performing a minimum of 20 LB (134).

The British and Irish Committee on Higher Medical Training has approved a curriculum for training in gastroenterology that states that “all trainees should be thoroughly familiar with the indications, methods, and risks of percutaneous LB, including those performed under ultrasonographic control, and should have practical experience of a minimum of 50 procedures” (135).

No data show that the experience of the person performing LB has any effect on the complication rate (136). In 1991, a British Society of Gastroenterology audit, however, found that the frequency of complications was slightly higher if the operator had performed fewer than 20 LB (3.2%, 1.1% if the operator had performed >100 LB). No difference in complication rates was seen between adult gastroenterologists and general physicians (101). In 1 report, physician assistants observed 10 LB procedures, practiced on inanimate objects, and then performed 30 LB under supervision. Adequate tissue was obtained in 99.1% of attempts after a single pass and in 99.8% after 2 passes, with a mean tissue length of 3.2 cm (137). In another study, after observing 64 LB performed by a certified ultrasonography technician, a single hepatologist without previous ultrasonographic experience performed 101 LB independently with no statistical difference in terms of complications or of adequacy of the hepatic tissue obtained (138). The suggestion of the panel is to perform a minimum of 20 LB with supervision.

ROLE OF LB IN THE FUTURE

In the modern era, the goals of optimal clinical management remain unchanged: the patient should undergo minimally invasive procedures with maximal diagnostic and management yields and optimal outcome. Conventional diagnostic methods recently have been modified at the expense of traditional tissue diagnosis in areas of liver disease in which noninvasive methods provide comparable information. In monitoring activity of disease and assessing results of treatment, the study of liver tissue will, however, continue to be irreplaceable in the foreseeable future. In addition, the need will persist to correlate clinical and biochemical phenotypes with morphological findings, via both imaging studies and histopathological approaches, using new techniques for existing conditions, but also applying old methods in novel, emerging conditions. Clinicians will need to achieve a balance between, on one hand, patient safety and convenience and, on the other, scientific and technological advances in the present dynamic environment (139).

REFERENCES

- Menghini G, Carnevali O, Orlandi F, et al. Clinical evaluation of liver biopsy: considerations on four year experiences. *Prog Med (Napoli)* 1953;9:1–10.
- Menghini G. One-second biopsy of the liver—problems of its clinical application. *N Engl J Med* 1970;283:582–5.
- Yang JG, Ma DQ, Peng Y, et al. Comparison of different diagnostic methods for differentiating biliary atresia from idiopathic neonatal hepatitis. *Clin Imaging* 2009;33:439–46.
- Russo P, Magee JC, Boitnott J, et al. Design and validation of the biliary atresia research consortium histologic assessment system for cholestasis in infancy. *Clin Gastroenterol Hepatol* 2011;9:357–62e2.
- Hartley J, Harnden A, Kelly D. Biliary atresia. *BMJ* 2010;340:c2383.
- Azar G, Beneck D, Lane B, et al. Atypical morphologic presentation of biliary atresia and value of serial liver biopsies. *J Pediatr Gastroenterol Nutr* 2002;34:212–5.
- Bull LN, Carlton VE, Stricker NL, et al. Genetic and morphological findings in progressive familial intrahepatic cholestasis (Byler disease [PFIC-1] and Byler syndrome): evidence for heterogeneity. *Hepatology* 1997;26:155–64.
- Gonzales E, Gerhardt MF, Fabre M, et al. Oral cholic acid for hereditary defects of primary bile acid synthesis: a safe and effective long-term therapy. *Gastroenterology* 2009;137:1310–20e1-3.
- Subramaniam P, Clayton PT, Portmann BC, et al. Variable clinical spectrum of the most common inborn error of bile acid metabolism—3beta-hydroxy-Delta 5-C27-steroid dehydrogenase deficiency. *J Pediatr Gastroenterol Nutr* 2010;50:61–6.
- Melter M, Rodeck B, Kardorff R, et al. Progressive familial intrahepatic cholestasis: partial biliary diversion normalizes serum lipids and improves growth in noncirrhotic patients. *Am J Gastroenterol* 2000;95:3522–8.
- Kalicinski PJ, Ismail H, Jankowska I, et al. Surgical treatment of progressive familial intrahepatic cholestasis: comparison of partial external biliary diversion and ileal bypass. *Eur J Pediatr Surg* 2003;13:307–11.
- Emerick KM, Elias MS, Melin-Aldana H, et al. Bile composition in Alagille syndrome and PFIC patients having Partial external biliary diversion. *BMC Gastroenterol* 2008;8:47.
- Jacquemin E, De Vree JM, Cresteil D, et al. The wide spectrum of multidrug resistance 3 deficiency: from neonatal cholestasis to cirrhosis of adulthood. *Gastroenterology* 2001;120:1448–58.
- Chen HL, Chang PS, Hsu HC, et al. Progressive familial intrahepatic cholestasis with high gamma-glutamyltranspeptidase levels in Taiwanese infants: role of MDR3 gene defect? *Pediatr Res* 2001;50:50–5.
- Colombo C, Vajro P, Degiorgio D, et al. Clinical features and genotype-phenotype correlations in children with progressive familial intrahepatic cholestasis type 3 related to ABCB4 mutations. *J Pediatr Gastroenterol Nutr* 2011;52:73–83.
- Anheim M, Chamouard P, Rudolf G, et al. Unexpected combination of inherited chorea-acanthocytosis with MDR3 (ABCB4) defect mimicking Wilson's disease. *Clin Genet* 2010;78:294–5.
- Ramraj R, Finegold MJ, Karpén SJ. Progressive familial intrahepatic cholestasis type 3: overlapping presentation with Wilson disease. *Clin Pediatr (Phila)* 2012;51:689–91.
- Subramaniam P, Knisely A, Portmann B, et al. Diagnosis of Alagille syndrome-25 years of experience at King's College Hospital. *J Pediatr Gastroenterol Nutr* 2011;52:84–9.
- Lykavieris P, Hadchouel M, Chardot C, et al. Outcome of liver disease in children with Alagille syndrome: a study of 163 patients. *Gut* 2001;49:431–5.
- Bakula A, Socha P, Pawlowska J, et al. Good and bad prognosis of alpha-1-antitrypsin deficiency in children: when to list for liver transplantation. *Transplant Proc* 2007;39:3186–8.
- Francavilla R, Castellana SP, Hadzic N, et al. Prognosis of alpha-1-antitrypsin deficiency-related liver disease in the era of paediatric liver transplantation. *J Hepatol* 2000;32:986–92.
- Squires RH Jr, Shneider BL, Bucuvalas J, et al. Acute liver failure in children: the first 348 patients in the pediatric acute liver failure study group. *J Pediatr* 2006;148:652–8.
- Lee WM, Squires RH Jr, Nyberg SL, et al. Acute liver failure: summary of a workshop. *Hepatology* 2008;47:1401–15.
- Dhawan A, Cheeseman P, Mieli-Vergani G. Approaches to acute liver failure in children. *Pediatr Transplant* 2004;8:584–8.
- Lee D, Chitturi S, Kench J, et al. Transjugular liver biopsy effecting changes in clinical management. *Australas Radiol* 2003;47:117–20.
- Hind JMQA, Taylor RM, Kortsalioudakis C, et al. Role of liver histology in the management of acute liver failure in children. *Hepatology* 2007;46 (S1):725A–821A.
- Miraglia R, Luca A, Gruttadauria S, et al. Contribution of transjugular liver biopsy in patients with the clinical presentation of acute liver failure. *Cardiovasc Intervent Radiol* 2006;29:1008–10.
- Habdank K, Restrepo R, Ng V, et al. Combined sonographic and fluoroscopic guidance during transjugular hepatic biopsies performed in children: a retrospective study of 74 biopsies. *AJR Am J Roentgenol* 2003;180:1393–8.

29. Iorio R, Sepe A, Giannattasio A, et al. Hypertransaminasemia in childhood as a marker of genetic liver disorders. *J Gastroenterol* 2005;40:820–6.
30. Boldrini R, Devito R, Biselli R, et al. Wolman disease and cholesteryl ester storage disease diagnosed by histological and ultrastructural examination of intestinal and liver biopsy. *Pathol Res Pract* 2004;200:231–40.
31. Patrick AD, Willcox P, Stephens R, et al. Prenatal diagnosis of Wolman's disease. *J Med Genet* 1976;13:49–51.
32. Hamilton J, Jones I, Srivastava R, et al. A new method for the measurement of lysosomal acid lipase in dried blood spots using the inhibitor Lalistat 2. *Clin Chim Acta* 2012;413:1207–10.
33. Vajro P, Lenta S, Socha P, et al. Diagnosis of nonalcoholic fatty liver disease in children and adolescents: position paper of the ESPGHAN Hepatology Committee. *J Pediatr Gastroenterol Nutr* 2012;54:700–13.
34. Mieli-Vergani G, Heller S, Jara P, et al. Autoimmune hepatitis. *J Pediatr Gastroenterol Nutr* 2009;49:158–64.
35. Ferenci P, Caca K, Loudianos G, et al. Diagnosis and phenotypic classification of Wilson disease. *Liver Int* 2003;23:139–42.
36. Dhawan A, Taylor RM, Cheeseman P, et al. Wilson's disease in children: 37-year experience and revised King's score for liver transplantation. *Liver Transpl* 2005;11:441–8.
37. Fontana RJ, Seeff LB, Andrade RJ, et al. Standardization of nomenclature and causality assessment in drug-induced liver injury: summary of a clinical research workshop. *Hepatology* 2010;52:730–42.
38. Suzuki A, Brunt EM, Kleiner DE, et al. The use of liver biopsy evaluation in discrimination of idiopathic autoimmune hepatitis versus drug-induced liver injury. *Hepatology* 2011;54:931–9.
39. Watkins PB, Seeff LB. Drug-induced liver injury: summary of a single topic clinical research conference. *Hepatology* 2006;43:618–31.
40. Wang SZ, Gao S, Liu YM, et al. Clinical characteristics of drug-induced liver injury in 31 pediatric cases. *Zhonghua Gan Zang Bing Za Zhi* 2012;20:193–5.
41. Devarbhavi H, Karanth D, Prasanna KS, et al. Drug-Induced liver injury with hypersensitivity features has a better outcome: a single-center experience of 39 children and adolescents. *Hepatology* 2011;54:1344–50.
42. LaRusso NF, Shneider BL, Black D, et al. Primary sclerosing cholangitis: summary of a workshop. *Hepatology* 2006;44:746–64.
43. de Lonlay P, Seta N, Barrot S, et al. A broad spectrum of clinical presentations in congenital disorders of glycosylation I: a series of 26 cases. *J Med Genet* 2001;38:14–9.
44. Mandato C, Brive L, Miura Y, et al. Cryptogenic liver disease in four children: a novel congenital disorder of glycosylation. *Pediatr Res* 2006;59:293–8.
45. Gunay-Aygun M, Avner ED, Bacallao RL, et al. Autosomal recessive polycystic kidney disease and congenital hepatic fibrosis: summary statement of a first National Institutes of Health/Office of Rare Diseases conference. *J Pediatr* 2006;149:159–64.
46. Jonas MM, Mizerski J, Badia IB, et al. Clinical trial of lamivudine in children with chronic hepatitis B. *N Engl J Med* 2002;346:1706–13.
47. Jara P, Bortolotti F. Interferon-alpha treatment of chronic hepatitis B in childhood: a consensus advice based on experience in European children. *J Pediatr Gastroenterol Nutr* 1999;29:163–70.
48. Bortolotti F, Verucchi G, Camma C, et al. Long-term course of chronic hepatitis C in children: from viral clearance to end-stage liver disease. *Gastroenterology* 2008;134:1900–7.
49. Sokal EM, Bourgeois A, Stephenne X, et al. Peginterferon alfa-2a plus ribavirin for chronic hepatitis C virus infection in children and adolescents. *J Hepatol* 2010;52:827–31.
50. Guido M, Bortolotti F, Leandro G, et al. Fibrosis in chronic hepatitis C acquired in infancy: is it only a matter of time? *Am J Gastroenterol* 2003;98:660–3.
51. Paya CV, Holley KE, Wiesner RH, et al. Early diagnosis of cytomegalovirus hepatitis in liver transplant recipients: role of immunostaining, DNA hybridization and culture of hepatic tissue. *Hepatology* 1990;12:119–26.
52. Koch DG, Christiansen L, Lazarchick J, et al. Posttransplantation lymphoproliferative disorder—the great mimic in liver transplantation: appraisal of the clinicopathologic spectrum and the role of Epstein-Barr virus. *Liver Transpl* 2007;13:904–12.
53. Barkholt L, Reinhold FP, Teramoto N, et al. Polymerase chain reaction and in situ hybridization of Epstein-Barr virus in liver biopsy specimens facilitate the diagnosis of EBV hepatitis after liver transplantation. *Transpl Int* 1998;11:336–44.
54. Nuckols JD, Baron PW, Stenzel TT, et al. The pathology of liver-localized post-transplant lymphoproliferative disease: a report of three cases and a review of the literature. *Am J Surg Pathol* 2000;24:733–41.
55. Czauderna P, Mackinlay G, Perilongo G, et al. Hepatocellular carcinoma in children: results of the first prospective study of the International Society of Pediatric Oncology group. *J Clin Oncol* 2002;20:2798–804.
56. Ovchinsky N, Moreira RK, Lefkowitz JH, et al. Liver biopsy in modern clinical practice: a pediatric point-of-view. *Adv Anat Pathol* 2012;19:250–62.
57. Hubscher S. What does the long-term liver allograft look like for the pediatric recipient? *Liver Transpl* 2009;15 (suppl 2):S19–24.
58. Berenguer M, Rayon JM, Prieto M, et al. Are posttransplantation protocol liver biopsies useful in the long term? *Liver Transpl* 2001;7:790–6.
59. Mells G, Mann C, Hubscher S, et al. Late protocol liver biopsies in the liver allograft: a neglected investigation? *Liver Transpl* 2009;15:931–8.
60. Miyagawa-Hayashino A, Yoshizawa A, Uchida Y, et al. Progressive graft fibrosis and donor-specific human leukocyte antigen antibodies in pediatric late liver allografts. *Liver Transpl* 2012;18:1333–42.
61. Ekong UD. The long-term liver graft and protocol biopsy: do we want to look? What will we find? *Curr Opin Organ Transplant* 2011;16:505–8.
62. Demetris A. Importance of liver biopsy findings in immunosuppression management: biopsy monitoring and working criteria for patients with operational tolerance. *Liver Transpl* 2012;18:1154–70.
63. Rockey DC, Caldwell SH, Goodman ZD, et al. Liver biopsy. *Hepatology* 2009;49:1017–44.
64. Lindor KD, Bru C, Jorgensen RA, et al. The role of ultrasonography and automatic-needle biopsy in outpatient percutaneous liver biopsy. *Hepatology* 1996;23:1079–83.
65. Siegel CA, Silas AM, Suriawinata AA, et al. Liver biopsy 2005: when and how? *Cleve Clin J Med* 2005;72:199–210, 08 passim.
66. Lebrech D, Goldfarb G, Degott C, et al. Transvenous liver biopsy: an experience based on 1000 hepatic tissue samplings with this procedure. *Gastroenterology* 1982;83:338–40.
67. McAfee JH, Keeffe EB, Lee RG, et al. Transjugular liver biopsy. *Hepatology* 1992;15:726–32.
68. Smith TP, Presson TL, Heneghan MA, et al. Transjugular biopsy of the liver in pediatric and adult patients using an 18-gauge automated core biopsy needle: a retrospective review of 410 consecutive procedures. *AJR Am J Roentgenol* 2003;180:167–72.
69. Esposito C, Garipoli V, Vecchione R, et al. Laparoscopy-guided biopsy in diagnosis of liver disorders in children. *Liver* 1997;17:288–92.
70. Vajro P, Hadchouel P, Hadchouel M, et al. Incidence of cirrhosis in children with chronic hepatitis. *J Pediatr* 1990;117:392–6.
71. Esposito C, Garipoli V, Pasquale M, et al. Percutaneous blind needle biopsy versus combined laparoscopic excisional and guided needle biopsy in the diagnosis of liver disorders in pediatric patients. *Ital J Gastroenterol Hepatol* 1997;29:179–81.
72. Bravo AA, Sheth SG, Chopra S. Liver biopsy. *N Engl J Med* 2001;344:495–500.
73. Sporea I, Popescu A, Sirlu R. Why, who and how should perform liver biopsy in chronic liver diseases. *World J Gastroenterol* 2008;14:3396–402.
74. El-Shabrawi MH, El-Karakasy HM, Okahsa SH, et al. Outpatient blind percutaneous liver biopsy in infants and children: is it safe? *Saudi J Gastroenterol* 2012;18:26–33.
75. Palmer T, Georgiades I, Treanor D, et al. Improved tissue sections for medical liver biopsies: a comparison of 16 vs 18 g biopsy needles using digital pathology. *J Clin Pathol* 2014;67:415–9.
76. Grant A, Neuberger J. Guidelines on the use of liver biopsy in clinical practice. British Society of Gastroenterology. *Gut* 1999;45 (suppl 4):IV1–1.
77. Maharaj B, Bhoora IG. Complications associated with percutaneous needle biopsy of the liver when one, two or three specimens are taken. *Postgrad Med J* 1992;68:964–7.

78. Linder H. Grenzen und Gefahren der perkutanen Leberbiopsie mit der Menghini-Nadel: Erfahrungen bei 80,000 Leberbiopsien. *Dtsch Med Wochenschr* 1967;92:1751-7.
79. Pietrobattista A, Fruwirth R, Natali G, et al. Is juvenile liver biopsy unsafe? Putting an end to a common misapprehension. *Pediatr Radiol* 2009;39:959-61.
80. Piccinino F, Sagnelli E, Pasquale G, et al. Complications following percutaneous liver biopsy. A multicentre retrospective study on 68,276 biopsies. *J Hepatol* 1986;2:165-73.
81. van Leeuwen DJ, Wilson L, Crowe DR. Liver biopsy in the mid-1990s: questions and answers. *Semin Liver Dis* 1995;15:340-59.
82. Garcia-Tsao G, Boyer JL. Outpatient liver biopsy: how safe is it? *Ann Intern Med* 1993;118:150-3.
83. Janes CH, Lindor KD. Outcome of patients hospitalized for complications after outpatient liver biopsy. *Ann Intern Med* 1993;118:96-8.
84. Gonzalez-Vallina R, Alonso EM, Rand E, et al. Outpatient percutaneous liver biopsy in children. *J Pediatr Gastroenterol Nutr* 1993;17:370-5.
85. Perrault J, McGill DB, Ott BJ, et al. Liver biopsy: complications in 1000 inpatients and outpatients. *Gastroenterology* 1978;74:103-6.
86. Sherlock S, Dick R, Van Leeuwen DJ. Liver biopsy today. The Royal Free Hospital experience. *J Hepatol* 1985;1:75-85.
87. Stone MA, Mayberry JF. An audit of ultrasound guided liver biopsies: a need for evidence-based practice. *Hepatogastroenterology* 1996;43:432-4.
88. McGill DB, Rakela J, Zinsmeister AR, et al. A 21-year experience with major hemorrhage after percutaneous liver biopsy. *Gastroenterology* 1990;99:1396-400.
89. Cohen MB, HH AK, Lambers D, et al. Complications of percutaneous liver biopsy in children. *Gastroenterology* 1992;102:629-32.
90. Hoffer FA. Liver biopsy methods for pediatric oncology patients. *Pediatr Radiol* 2000;30:481-8.
91. Westheim BH, Ostensen AB, Aagaens I, et al. Evaluation of risk factors for bleeding after liver biopsy in children. *J Pediatr Gastroenterol Nutr* 2012;55:82-7.
92. Eisenberg E, Konopniki M, Veitsman E, et al. Prevalence and characteristics of pain induced by percutaneous liver biopsy. *Anesth Analg* 2003;96:1392-6.
93. Hurwitz LM, Thompson WM. Calcified hepatic arteriovenous fistula found after biopsy of the liver: unusual cause of calcification in the right upper quadrant. *AJR Am J Roentgenol* 2002;179:1293-5.
94. Hashimoto E, Ludwig J, MacCarty RL, et al. Hepatoportal arteriovenous fistula: morphologic features studied after orthotopic liver transplantation. *Hum Pathol* 1989;20:707-9.
95. Otake Y, Hashimoto T, Shimizu Y, et al. Formation of a fatal arterioportal fistula following needle liver biopsy in a child with a living-related liver transplant: report of a case. *Surg Today* 1995;25:916-9.
96. Jabbour N, Reyes J, Zajko A, et al. Arterioportal fistula following liver biopsy. Three cases occurring in liver transplant recipients. *Dig Dis Sci* 1995;40:1041-4.
97. Falkenstein K, Flynn L, Dunn S, et al. Arterial-venous fistulas following pediatric liver transplant case studies. *Pediatr Transplant* 2007;11:683-8.
98. Kalambokis G, Manousou P, Vibhakorn S, et al. Transjugular liver biopsy—indications, adequacy, quality of specimens, and complications—a systematic review. *J Hepatol* 2007;47:284-94.
99. van der Poorten D, Kwok A, Lam T, et al. Twenty-year audit of percutaneous liver biopsy in a major Australian teaching hospital. *Intern Med J* 2006;36:692-9.
100. Smith TP, McDermott VG, Ayoub DM, et al. Percutaneous transhepatic liver biopsy with tract embolization. *Radiology* 1996;198:769-74.
101. Gilmore IT, Burroughs A, Murray-Lyon IM, et al. Indications, methods, and outcomes of percutaneous liver biopsy in England and Wales: an audit by the British Society of Gastroenterology and the Royal College of Physicians of London. *Gut* 1995;36:437-41.
102. Livraghi T, Lombardi C, Mascia G. Bile peritonitis: another complication after fine-needle biopsy. *Diagn Imaging* 1983;52:33-5.
103. Clark RA, Frey RT, Colley DP, et al. Transcatheter embolization of hepatic arteriovenous fistulas for control of hemobilia. *Gastrointest Radiol* 1981;6:353-6.
104. Bubak ME, Porayko MK, Krom RA, et al. Complications of liver biopsy in liver transplant patients: increased sepsis associated with choledochojunostomy. *Hepatology* 1991;14:1063-5.
105. Amaral JG, Schwartz J, Chait P, et al. Sonographically guided percutaneous liver biopsy in infants: a retrospective review. *AJR Am J Roentgenol* 2006;187:W644-9.
106. Tobin MV, Gilmore IT. Plugged liver biopsy in patients with impaired coagulation. *Dig Dis Sci* 1989;34:13-5.
107. Little AF, Ferris JV, Dodd GD 3rd et al. Image-guided percutaneous hepatic biopsy: effect of ascites on the complication rate. *Radiology* 1996;199:79-83.
108. Atar E, Ben Ari Z, Bachar GN, et al. A comparison of transjugular and plugged-percutaneous liver biopsy in patients with contraindications to ordinary percutaneous liver biopsy and an “in-house” protocol for selecting the procedure of choice. *Cardiovasc Intervent Radiol* 2010;33:560-4.
109. Sawyerr AM, McCormick PA, Tennyson GS, et al. A comparison of transjugular and plugged-percutaneous liver biopsy in patients with impaired coagulation. *J Hepatol* 1993;17:81-5.
110. Kamphuisen PW, Wiersma TG, Mulder CJ, et al. Plugged-percutaneous liver biopsy in patients with impaired coagulation and ascites. *Pathophysiol Haemost Thromb* 2002;32:190-3.
111. Sterling RPD, Post T, Herberger T, et al. Increasing size of true cut needle is associated with increased bleeding in porcine liver biopsies. *Hepatology* 1995;22:694A.
112. Lykavieris P, Crosnier C, Trichet C, et al. Bleeding tendency in children with Alagille syndrome. *Pediatrics* 2003;111:167-70.
113. Mannucci PM, Remuzzi G, Pusineri F, et al. Deamino-8-D-arginine vasopressin shortens the bleeding time in uremia. *N Engl J Med* 1983;308:8-12.
114. Remuzzi G, Pusineri F. Coagulation defects in uremia. *Kidney Int Suppl* 1988;24:S13-7.
115. Gissen P, Tee L, Johnson CA, et al. Clinical and molecular genetic features of ARC syndrome. *Hum Genet* 2006;120:396-409.
116. Azzam RK, Alonso EM, Emerick KM, et al. Safety of percutaneous liver biopsy in infants less than three months old. *J Pediatr Gastroenterol Nutr* 2005;41:639-43.
117. Tripodi A, Chantarangkul V, Primignani M, et al. Point-of-care coagulation monitors calibrated for the international normalized ratio for cirrhosis (INRliver) can help to implement the INRliver for the calculation of the MELD score. *J Hepatol* 2009;51:288-95.
118. Ewe K. Bleeding after liver biopsy does not correlate with indices of peripheral coagulation. *Dig Dis Sci* 1981;26:388-93.
119. Tripodi A, Chantarangkul V, Primignani M, et al. The international normalized ratio calibrated for cirrhosis (INR(liver)) normalizes prothrombin time results for model for end-stage liver disease calculation. *Hepatology* 2007;46:520-7.
120. Pettersson M, Fischler B, Petrini P, et al. Recombinant FVIIa in children with liver disease. *Thromb Res* 2005;116:185-97.
121. Brown JB, Emerick KM, Brown DL, et al. Recombinant factor VIIa improves coagulopathy caused by liver failure. *J Pediatr Gastroenterol Nutr* 2003;37:268-72.
122. Boberg KM, Brosstad F, Egeland T, et al. Is a prolonged bleeding time associated with an increased risk of hemorrhage after liver biopsy? *Thromb Haemost* 1999;81:378-81.
123. Oshrine B, Lehmann LE, Duncan CN. Safety and utility of liver biopsy after pediatric hematopoietic stem cell transplantation. *J Pediatr Hematol Oncol* 2011;33:e92-7.
124. Zakaria N, Knisely A, Portmann B, et al. Acute sickle cell hepatopathy represents a potential contraindication for percutaneous liver biopsy. *Blood* 2003;101:101-3.
125. Rungsinaporn K, Phaisakamas T. Frequency of abnormalities detected by upper abdominal ultrasound. *J Med Assoc Thai* 2008;91:1072-5.
126. Lee SE, Kim HY, Jung SE, et al. Situs anomalies and gastrointestinal abnormalities. *J Pediatr Surg* 2006;41:1237-42.

127. Kelly D. Differential diagnosis and useful investigations. In: Kelly D, ed. *Diseases of the Liver and Biliary System in Children, 3rd ed.* Oxford: Blackwell Publishing; 2008: 21–34.
128. Pietrobattista A, Alterio A, Natali G, et al. Needle biopsy in children with liver diseases. In: Mizuguchi Y, ed. *Liver Biopsy in Modern Medicine.* Rijeka, Croatia: InTech; 2011.
129. Sharma P, McDonald GB, Banaji M. The risk of bleeding after percutaneous liver biopsy: relation to platelet count. *J Clin Gastroenterol* 1982;4:451–3.
130. Alagille D, Odievre M. *Maladies du Foie et des Voies Biliaires chez l'Enfant.* Paris: Flammarion Medicine Sciences; 1978.
131. Ratziu V, Charlotte F, Heurtier A, et al. Sampling variability of liver biopsy in nonalcoholic fatty liver disease. *Gastroenterology* 2005; 128:1898–906.
132. UC San Diego Health Sciences, Hepatology Liver Biopsy Guidelines. <http://gastro.ucsd.edu/liver/Documents/Liver%20Biopsy%20Guidelines.pdf>. Accessed September 1, 2014.
133. Rudolph CD, Winter HS, et al., NASPGN Executive Council NT. NASPGN guidelines for training in pediatric gastroenterology. *J Pediatr Gastroenterol Nutr* 1999;29:S1–26.
134. American Association for the Study of Liver Diseases; American College of Gastroenterology; American Gastroenterological Association; American Society for Gastrointestinal Endoscopy. Training the gastroenterologist of the future: the Gastroenterology Core Curriculum. *Gastroenterology* 2003;124:1055–104.
135. Shah S, Mayberry JF, Wicks ACB, et al. Liver biopsy under ultrasound control: implications for training in the Calman era. *Gut* 1999;45:628–9.
136. Westheim BH, Aagenaes I, Ostensen AB, et al. Effect of operator experience and frequency of procedure performance on complication rate after ultrasound-guided percutaneous liver biopsies. *J Pediatr Gastroenterol Nutr* 2013;57:638–43.
137. Gunneson TJ, Menon KV, Wiesner RH, et al. Ultrasound-assisted percutaneous liver biopsy performed by a physician assistant. *Am J Gastroenterol* 2002;97:1472–5.
138. Riley TR 3rd. How often does ultrasound marking change the liver biopsy site? *Am J Gastroenterol* 1999;94:3320–2.
139. Peppercorn J, Shapira I, Deshields T, et al. Ethical aspects of participation in the Database of Genotypes and Phenotypes of the National Center for Biotechnology Information: the Cancer and Leukemia Group B Experience. *Cancer* 2012;118:5060–8.