

Diagnosis, management, and prevention of button battery ingestion in childhood: an ESPGHAN position paper

Amani **Mubarak**¹, Marc A **Benninga**², Ilse **Broekaert**³, Jernej **Dolinsek**⁴,
Matjaž **Homan**⁵, Emmanuel **Mas**⁶, Erasmo **Miele**⁷, Corina **Pienar**⁸, Nikhil **Thapar**^{9,10},
Mike **Thomson**¹¹, Christos **Tzivinikos**¹², Lissy de **Ridder**¹³

1: Department of Pediatric Gastroenterology, University Medical Center Utrecht, Utrecht, The Netherlands

2: Emma Children's Hospital, Amsterdam University Medical Center, Amsterdam, The Netherlands

3: Department of Paediatrics, Faculty of Medicine and University Hospital Cologne, University of Cologne, Cologne, Germany

4: Paediatric Gastroenterology, Hepatology and Nutrition Unit, Department of Paediatrics, UMC Maribor, Slovenia.

5: Department of Gastroenterology, Hepatology, and Nutrition, Faculty of Medicine, University Children's Hospital, University of Ljubljana, Ljubljana, Slovenia

6: Unité de Gastroentérologie, Hépatologie, Nutrition et Maladies Héréditaires du Métabolisme, Hôpital des Enfants, CHU de Toulouse, F-31300, France et IRSD, Université de Toulouse, INSERM, INRA, ENVT, UPS, Toulouse, France

7: Department of Translational Medical Science, Section of Paediatrics, University of Naples "Federico II", Naples, Italy

8: Victor Babes University of Medicine and Pharmacy, Timisoara, Romania.

9: Department of Paediatric Gastroenterology, Great Ormond Street Hospital, London, United Kingdom

10: Department of Gastroenterology, Hepatology and Liver Transplant, Queensland Children's Hospital, Brisbane, Australia

11. Centre for Paediatric Gastroenterology and International Academy of Paediatric Endoscopy Training, Sheffield Children's Hospital, Sheffield, United Kingdom

12. Department of Pediatric Gastroenterology, Al Jalila Children's Specialty Hospital, Dubai, United Arab Emirates

13. Department of Pediatric Gastroenterology, Sophia Children's Hospital/Erasmus Medical Center, Rotterdam, The Netherlands

Corresponding author: Lissy de Ridder, Department of Pediatric Gastroenterology, Erasmus Medical Center-Sophia Children's Hospital, Wytemaweg 80, 3015 CN Rotterdam, The Netherlands. Telephone: 003117040704. Fax: 0031107030425. E-mail: l.deridder@erasmusmc.nl

Funding: none

Conflicts of interests: Amani Mubarak: none; Marc Benninga: none; Ilse Broekaert: none; Jernej Dolinsek: none; Matjaž Homan: none; Emmanuel Mas: none; Erasmo Miele received grant or research support from Nestle Italy and Nutricia Italy, served as a member of the advisory board for Abbvie, and received payment/honoraria from Ferring; Corina Pienar: none; Nikhil Thapar: Consultant/Speaker for Nutricia and Takeda; Mike Thomson: none; Christos Tzivinikos: none; Lissy de Ridder: none.

ESPGHAN DISCLAIMER “ESPGHAN is not responsible for the practices of physicians and provides guidelines and position papers as indicators

Abstract

Button batteries (BB) remain a health hazard to children as ingestion might lead to life-threatening complications, especially if the battery is impacted in the esophagus. Worldwide initiatives have been set up in order to prevent and also timely diagnose and manage button battery (BB) ingestions. An European Society for Paediatric Gastroenterology Hepatology and Nutrition (ESPGHAN) task force for BB ingestions has been founded which aimed to contribute to reducing the health risks related to this event. It is important to focus on the European setting, next to other worldwide initiatives, to develop and implement effective management strategies. As one of the first initiatives of the ESPGHAN task force, this ESPGHAN position paper has been written. The literature is summarized, and prevention strategies are discussed focusing on some controversial topics. An algorithm for the diagnosis and management of BB ingestions is presented and compared to previous guidelines (NASPGHAN, National Poison Center). In agreement with earlier guidelines, immediate localization of the BB is important and in case of esophageal impaction the BB should be removed instantly (preferably <2 hours). Honey and sucralfate can be considered in ingestions ≤ 12 hours while waiting for endoscopic removal but should not delay it. In case of delayed diagnosis (first confirmation of the BB on x-ray >12 hours after ingestion or time point of removal >12 hours after ingestion) and esophageal impaction the guideline suggests to perform a CT scan in order to evaluate for vascular injury before removing the battery. In delayed diagnosis, even if the battery has passed the esophagus, endoscopy to screen for esophageal damage and a CT scan to rule out vascular injury should be considered even in asymptomatic children. In asymptomatic patients with early diagnosis (≤ 12 hours after ingestion) and position of the BB beyond the esophagus one can monitor with repeat x-ray (if not already evacuated in stool) in 7-14 days which is different from previous guidelines where repeat x-ray and removal is recommended after 2-4 days and is also based on age. Finally, prevention strategies are discussed in this paper.

Key-words: foreign body, endoscopy, esophageal perforation, pediatric, caustic ingestion

Abbreviations

BB: button battery

ENT: ear nose and throat

ESPGHAN: The European Society for Paediatric Gastroenterology Hepatology and Nutrition.

BBTF: National Button Battery Task Force

What is known

- Button batteries (BB) ingestions pose a huge health risk for the pediatric population potentially leading to severe morbidity and even mortality.
- Esophageal battery impaction has the highest risk of complications, especially in children <6 years of age and in batteries >20 mm in diameter.
- Prevention strategies include raising public awareness, cooperation with industry to develop safer battery compartments in products, and negotiations with authorities on legislative issues to minimize the risk of ingestion.

What is new

- The European Society for Paediatric Gastroenterology Hepatology and Nutrition (ESPGHAN) task force for BB ingestions aims to prevent morbidity and mortality due to BB injuries.
- The first European position paper with clinical guidance has been developed and discusses controversial topics regarding diagnosis and management of BB ingestions.

Introduction

An increasing number of button battery (BB) ingestions has been described worldwide, mainly due to the wide abundance of batteries in consumer electronics.^{1,2} This is a serious health issue as exposure to batteries may result in severe injury and even death, especially if they are impacted in the esophagus or if vascular or airway injury occurs due to subsequent fistulization (see supplementary file for an illustrative case, <http://links.lww.com/MPG/C191>).³ The European Society for Paediatric Gastroenterology Hepatology and Nutrition (ESPGHAN) task force for BB ingestions was founded as an ongoing initiative of pediatric gastroenterologists to prevent morbidity and mortality due to such ingestions. This is through raising public awareness and developing prevention strategies with the industry in the first place, and secondly by aiming for better diagnoses and treatment. By having such a task force in Europe, we will be able to do so more effectively because we will be able to use a more localized approach. Part of the strategy is also developing the first European clinical algorithm for the diagnosis and management of BB ingestions, which we do in this article. Although there are already American guidelines (NASPGHAN and the National Poison Center), some topics are still subject to debate and are discussed in more detail such as what to do with a BB that has already passed the esophagus in asymptomatic cases and whether honey or sucralfate should be used as a mitigation strategy post-ingestion. In this paper the ESPGHAN's view on these topics is discussed in more detail.

Methods

A systematic search of the literature was performed to identify publications relevant to the aims of this position paper. We performed a search with the following terms: ((coin AND cell) OR button) AND battery AND (ingestion OR consumption). We included randomized controlled trials, cohort studies, cross-sectional studies, clinical trials, epidemiological studies, systematic reviews, meta-analyses, and consensus statements/guidelines published in English up to May 2020. No limitation in the search period was made. We focused on epidemiology, pathophysiology and complications, diagnostics and treatment (clinical presentations, imaging, endoscopy, surgery), follow-up, prevention and public awareness and formulated clinical recommendations based on the literature.

Epidemiology

BB are found in many household electronics, hearing aids and toys. Changes in manufacturing over the years have led to larger and more powerful batteries. This has not only increased the risk of esophageal battery impaction but escalated the risk of developing severe complications even more.¹⁻⁴ According to recent data there was a seven-fold increase in the relative risk of severe morbidity due to BB ingestion in the last two decades.⁴ Of all children worldwide presenting with foreign body ingestion, the percentage of children with battery ingestion is estimated to be as high as ~7-25%.⁵⁻⁸ Most battery ingestions occur in children < 6 years of age with a peak at 1 year of age, which is also the age with the highest risk of complications.^{1,3} Illustratively, according to the US National Poison Center, there were 3467 BB ingestions (10.46 per million) in that country alone in calendar year 2019 including 53% in children <6 years of age, 1.5% who experienced severe complications, and

3 who have died.²⁰ Less is known about European ingestions, but these have been described in case reports and series.^{13, 42}

Pathophysiology and complications

Several theories have been hypothesized regarding the mechanism of injury in BB ingestions. Local pressure necrosis, corrosive damage from leakage of battery content, heavy metal toxicity and electric injury all seem to play a role.³ However, it is the electrolysis that seems to be the most significant mechanism. In case a battery contacts the esophageal tissue, a current is created with the human tissue being the connector of the circuit around the two battery poles. This leads to hydroxide ion formation at the negative pole, which in turn rapidly leads to pH rise causing tissue liquefaction and necrosis, comparable to damage occurring in the esophagus after alkaline liquid ingestion.⁹⁻¹¹ Transmural esophageal wall damage may occur leading to fistulization of both the esophageal wall and surrounding tissues (such as trachea, aorta or subclavian artery) leading to several life-threatening complications. Unfortunately, severe damage can occur within 2 hours after becoming lodged in the tissue.^{1,2} Possible complications after battery ingestions are listed in Table 1. A recent review by Varga et al. described 136191 cases (31 publications, age range 4 months-19 years) with battery ingestions (alkaline batteries 43.5%, zinc-air batteries 33%, silver oxide batteries 13.6%, lithium batteries 9.7%) in the respiratory and gastrointestinal tract and estimated the risk of complications to be 0.165% with a lethality of 0.04% (61 cases).³ This may sound low, nevertheless it should be emphasized that these preventable complications usually occur in otherwise healthy children. Fatal outcomes were due to massive hemorrhage because of fistula formation to the great vessels (aorto-esophageal fistula, right subclavian artery–esophageal fistula, esophageal-inferior thyroid arteries and veins in 44.3%) or suffocation secondary to blood aspiration and bronchopneumonia (11.4%). In the other cases (44.3%), the cause of death was unknown. Therefore, battery ingestions should be considered an important hazard to the pediatric population. Besides impaction of the battery in the esophagus, other factors increase the risk of complications. For instance, injuries are most commonly seen in batteries >20 mm in diameter and in children <6 years of age; this is because the batteries are relatively large in relation to the size of the esophagus and because they have a higher voltage compared to the smaller batteries.^{3,12} Logically, voltage and duration of the impaction are associated with more rapid and severe injury, although it is important to realize that even used or old batteries can retain sufficient residual voltage to cause tissue damage. Finally, the site of lodgement and adjacent tissue are predictive of complications. Batteries in the esophagus are typically the most problematic, probably due to the alkaline environment and increased risk of lodgement of foreign bodies in the esophagus, compared to the rest of the gastrointestinal tract. Moreover, due to the anatomical position and close contact with the respiratory tract and the major vessels, fistulization of the esophagus can be fatal (Figure 1). Various published case series have indicated that the location and orientation of the BB (negative pole) largely determines where the complications are most likely to occur (Figure 1).¹³⁻¹⁶ Caustic injury of the anterior wall of the esophagus prompts greater concern for vascular and tracheal injury, whereas posteriorly oriented inflammation has been associated with the development of spondylodiscitis.¹⁷ Anterior injury in the proximal esophagus should also prompt concern for thyroid artery involvement,

tracheo-esophageal fistula as well as vocal cord injury. Location in the mid esophagus should alert the greatest concern for aorto-esophageal fistulae.¹⁷

Batteries passing the esophagus usually pass the remaining gastrointestinal tract successfully: only 7% and 1.3% of overall complications occur in the stomach and small bowel, respectively.³ The battery gets stuck in the esophagus where after both poles are in close contact with the mucosa. Flow of electricity then leads to electrolysis. This is not the case in the stomach or small bowel. In the respiratory tract, complications in the nasal cavity are the most common and account for almost 16% of the complications.³

Although mucosal damage can occur within 2 hours after lodgement, development of complications mostly takes longer. Perforations are usually diagnosed within 2 days (rarely in the first 12 hours), but fistulas can present up to 4 weeks post-removal. Other complications such as esophageal strictures, spondylodiscitis or recurrent laryngeal nerve injury may take weeks or even months to develop.¹

Diagnosis and management

Figure 2 shows the diagnostic and management algorithm for battery ingestions and is discussed below. This algorithm is based on literature, previous guidelines and expert opinion, is simple to use and without different strategies dependent on age and size of the BB.¹⁸⁻²⁰

Clinical presentation

Recognizing BB ingestion is very important due to the extremely narrow 2-hour time window to remove BB impacted in the esophagus. Illustratively, most complications occur after unwitnessed ingestions leading to delayed diagnosis, as symptoms are variable and nonspecific.¹² Moreover, presenting symptoms differ according to the impaction site.^{2, 13, 21} Most witnessed ingestions present with acute gastrointestinal or respiratory symptoms such as vomiting, drooling, dysphagia, odynophagia, irritability, coughing, stridor and shortness of breath.^{2, 13, 21}

In unwitnessed ingestions, patients usually present when complications have already occurred, which can take a couple of hours to days (and even weeks). They usually present with hematemesis or hemoptysis, melena, abdominal pain, weight loss, chest pain, cough, stridor, hoarseness, sore throat, decreased range of motion of the neck, and fever. Patients can even present with an acute hemorrhage.^{2, 13, 21} Hence, it is of great importance to include foreign body aspiration/ingestion in the differential diagnosis of those cases even if the event was not witnessed.

Imaging

Two-view (anterior-posterior and lateral) X-ray is paramount to diagnose BB ingestion and confirm its location. It is important that the X-ray includes the entire neck, chest and abdomen to avoid missing a BB. In addition, close inspection of the image is necessary to identify a double ring or halo sign (Figure 3), which can distinguish a battery from a coin, and to determine the position of the negative side of the battery, which is the step-off side on the lateral film. However, one should be aware that in the slimmer batteries the ring or halo

may not be seen.² Finally, in a recent study using the density of a disc shaped object to distinguishes a coin from a battery was not successful.²²

Contrast studies with CT scanning (or MRI scanning after battery removal) are necessary to identify complications such as mediastinitis, fistulas and spondylodiscitis. Therefore, if patients have severe symptoms (at presentation or later on) indicative of possible complications (hemorrhage, hemodynamic problems, fever, respiratory symptoms, severe back pain, etc.), in case of mucosal injury identified during endoscopy it is advised to perform (serial) CT/MRI scans of the chest and neck. In delayed diagnosis of an esophageal impaction (first confirmation of the BB on x-ray >12 hours after ingestion or time point of removal >12 hours after ingestion) regardless of symptoms (serial) CT/MRI scans of the chest and neck should also be considered because the BB may have been lodged in the esophagus previously. In some cases a CT scan should even be done before endoscopy or endoscopic removal of the battery (see below). Note that MRI scans should never be performed before removal of a battery.

Endoscopy and surgery

Esophageal and airway impaction

When the battery is located in the esophagus immediate endoscopic removal is necessary, if possible within 2 hours of ingestion. Endoscopy should not be delayed even if the patient has eaten. This procedure should be performed under general anesthesia, after intubation of the patient thereby guaranteeing the airway. During endoscopy the mucosa should be inspected for extent, depth and location of the injury and the direction of the negative pole (side without the "+" sign and without the imprint) should be determined, as this is commonly the most damaged site. In case of significant mucosal damage, a nasogastric tube should be carefully placed endoscopically to maintain patency of the lumen and the patient should not receive any food by mouth until it is certain that no perforation or other complications have occurred (see follow-up section). In case of severe mucosal injury, delayed diagnosis or severe symptoms indicative of complications (such as bleeding), the (cardiothoracic) surgeon should be consulted and further imaging (CT-scan) should be performed even before the removal, as moving the battery might lead to acute perforation or haemorrhage through a fistula. In these cases, a joint approach with (cardiothoracic) surgeons and a cardiac catheter lab may be necessary. Endoscopic removal of the foreign body in the cardiac catheterization laboratory operation room with fluoroscopic guidance and arteriogram of the aorta allows direct visualization of the BB and its proximity to the aorta.

If the ingested battery is located in the airway or in the gastrointestinal tract above the clavicles, an Ear, Nose and Throat (ENT) doctor should be consulted to remove objects from the (upper) airways or upper part of the esophagus by rigid endoscopy.¹⁵ Sometimes it is necessary to perform the endoscopic procedures in collaboration (pediatric gastroenterologist and ENT doctor).

Location beyond the esophagus

Once the BB passed the esophagus almost three quarters of ingested batteries pass spontaneously within 4 days.²³ According to the NASPGHAN guideline removal is therefore

advised if a BB is still in the stomach after 2-4 days.²⁹ However, because virtually all (99.9%) batteries will still pass within 7-14 days while rarely causing complications, in this guideline we suggest a different approach in order to prevent (unnecessary) endoscopies.²³ Therefore based on this evidence we recommend that once the BB has passed the esophagus, asymptomatic cases should be followed-up after 7-14 days with an X-ray to confirm passage unless the battery has been noticed in the stools by the parents (parents should be instructed to check all stools).^{3,23} Only if the battery still has not passed the stomach by 7-14 days, endoscopic removal is necessary because by then the chance that it will pass spontaneously is expected to be minimal. The same advice goes for symptomatic patients with a battery located in the stomach, although the risk of complications in these patients is still low.

In case a battery is lodged in the small intestine and causes symptoms or does not pass spontaneously, surgical evaluation and removal is necessary, which fortunately is rarely needed. Once in the colon, a battery will almost always pass without intervention.

Nevertheless, it should be noted that the presence of a BB in the stomach or beyond does not exclude esophageal injury, especially in unwitnessed ingestions when the total time of BB exposure is unknown. BBs can transiently lodge in the esophagus and cause severe erosion and ongoing injury. Even after passage of the battery into the stomach or beyond, necrosis of the esophagus and surrounding tissues is an ongoing process that can lead to fistulization and associated severe outcome. In fact fatalities in children where the battery was initially discovered in the stomach have been reported.²⁰ In these cases, the cause of death was indeed likely due to esophageal injury that occurred from the BB transit. In addition, gastric necrosis of uncertain clinical significance has also been reported by BB within the stomach in asymptomatic children.²⁴⁻²⁷ Likewise, a recent multi-center retrospective cohort study of 68 patients with BB in the stomach has shown that after adjusting for age and symptoms, the likelihood of visualizing gastric damage among patients who had BBs removed after 12 hours post ingestion was 4.5 times higher compared with those with BB removal within 12 hours of ingestion. However, the clinical relevance of this seems low since data show that arrested battery progression did not lead to adverse outcomes.^{23, 28}

So presence of a BB in the stomach is most likely not permanently harmful to the stomach itself, but in specific circumstances (unwitnessed ingestion, delayed diagnosis (>12 hours after ingestion), symptomatic child) emergency endoscopy may still be indicated (to exclude esophageal damage). Another indication for endoscopic removal in the stomach is the co-ingestion of a magnet as this may lead to entrapment of the stomach or intestinal wall between the battery and the magnet causing necrosis. If a battery and magnet have already passed the stomach consultation of a surgeon is necessary; the patient should be either monitored closely or the battery and magnet should be removed surgically.

Our recommendations to remove gastric BBs in symptomatic cases, in patients with unwitnessed ingestion or delayed diagnosis (>12 hours after ingestion) and in case of a magnet co-ingestion are only slightly different from the recent recommendation of The National Button Battery Task Force (BBTF).²⁹ They recommend that in asymptomatic cases with BBs in the stomach outpatient observation may be considered on a case to case basis only if the patient is asymptomatic, has no history of prior esophageal disease, no co-ingestion with

magnet and if reliable follow up is possible. In other cases, a BB in the stomach should be removed.²⁹ At present there is not enough evidence to make stronger recommendations and larger prospective studies are needed to assess and stratify the risk for BB in the stomach.

Finally, in otherwise healthy children (especially toddlers) with acute onset of hematemesis, a high index of suspicion for battery ingestion should be maintained and diagnostics should be performed to expose the battery.

pH neutralization strategies to mitigate injury progression after ingestion

There are several reasons why timely removal of the battery may not be possible. For example, people living far from hospitals may not reach the hospital in time or the anesthetist may be unavailable due to another emergency intervention. Even in a large urban setting parents will often present to a health facility without pediatric endoscopy available and as a result precious or crucial time can be lost. In such cases, early and frequent ingestion of honey and if available sucralfate in the clinical setting may have the potential to reduce injury severity and improve patient outcomes.³⁰ However, it is important to realize that available data are based on promising *in vitro* and *in vivo* studies of piglets while human studies are still lacking. The mechanism of action is thought to be coating of the battery and thereby limiting electrolysis, but also neutralization of generated hydroxide as both honey and sucralfate are weak acids. Esophageal perforation is less likely in the first 12 hours after ingestion but this period does contain the peak of electrolysis activity and battery damage.³¹ Therefore, giving honey and/or sucralfate (1 g/10 mL suspension) might be considered within this time span. The advised dose for both is 10 mL (2 teaspoons) every 10 minutes with a maximum of 6 doses of honey and 3 doses of sucralfate respectively.^{20, 30}

One should be cautious in case of a delayed diagnosis, clinical suspicion of perforation, mediastinitis, sepsis, swallowing difficulties, allergies to honey or sucralfate and in children <1 year of age due to the small risk for infant botulism with honey intake.²⁰ Moreover, administration of honey or sucralfate should never be the reason to delay endoscopy removal, which is always the most important intervention. However, parents calling the emergency room may be advised to directly start giving honey if the history is strongly suggestive of BB ingestion and no signs of perforation are present.

Another mitigation strategy is neutralization of accumulated tissue hydroxide through acetic acid irrigation immediately following battery removal and may be considered an option.²⁰ This can be done with 50-150 ml 0.25% sterile acetic acid and should only be considered if signs of perforation are absent.^{20, 31-35} Again, it is important to note that this recommendation is based on a study in piglet esophagus preparations and a very small study in children ($n=6$).^{32, 34}

Anesthetists in every center should be aware of these pre-endoscopic removal strategies and get involved in the formulation of agreed protocols in an effort to avoid unnecessary delays in procedures. The entire specialty needs to be aware of the supporting data on general peri-operative considerations for management and potential complications of BB ingestion.^{33, 36}

Post removal evaluation and management and follow-up

All patients with mucosal injury after battery removal should be admitted to the hospital and monitored closely. In these patients a second look within 2-4 days after removal may be considered, as this could provide useful prognostic information.³⁷ A clear liquid diet may be started if there are no signs of perforation on esophagogram. The esophagogram can be performed 1-2 days after removal.²⁰ In complicated cases, this period should be extended until the patient is stabilized. When a clear liquid diet is tolerated, the diet can progress to soft foods. Depending on the severity of the injury, this may be considered to be continued up to for 4 weeks in order to avoid mechanical injury. Broad spectrum antibiotics to prevent mediastinitis should be considered in patients with severe injury, perforation and/or fever. As described above, (serial) MRI and CT scans are necessary to detect complications in patients with significant injury and/or delayed removal.

Long-term follow-up after removal depends on the presence and extent of esophageal injury. In case of injury, contrast esophagograms and/or repeat endoscopies are necessary to detect stricture formation, which can occur weeks after the incident. Early dilatation of a stricture will lead to better swallowing function; however, one should wait 4 weeks post-ingestion for the tissue to be healed.² Studies on long-term follow-up are scarce and are encouraged.

Exhaustive discharge instructions need to be provided outlining the signs and symptoms of upper gastro-intestinal bleeding. Use of acid blockade to minimize the impact of acid reflux on the esophageal injury has not been studied but seems well justified in cases of mucosal injury.

Prevention

As mentioned before, BB ingestions may cause severe morbidity and even mortality, and prevention is of extreme importance. According to Litovitz et al., in around 60% of cases, batteries are directly taken from an electrical device by the child himself while around 30% of the children ingest loose batteries. In approximately 10% of cases the batteries were obtained from the packaging.¹² In fact, Lahmar et al. calculated that almost 70% of the ingestions can be prevented with screw-secured compartments and individual blisters for batteries.³⁸ Therefore, securing the battery compartment of the product is the most important intervention to prevent battery ingestion. For this, it is essential to collaborate with industry to ensure a clear understanding of the hazards that come with poorly secured products.³⁹ Making the battery less attractive for children could be an option. With this perspective a new bitter coating has been developed by the industry, but of course we do not know yet whether this will truly decrease ingestions.⁴⁰ Regulatory agencies could also play a role by re-evaluating current battery legislation by implementing national strategies for improving the safety of button batteries, such as those by the Australian Competition and Consumer Commission.⁴¹ Additionally, raising public awareness making parents and caregivers aware of the dangers of battery ingestion is essential, as this could increase their cautiousness with products containing batteries and seek early medical attention when an ingestion has occurred. To raise public awareness, involvement of the industry, media, schools, family doctors and pediatricians (through National Pediatric Societies) is also very important. Finally, it is important that professionals are aware of the diagnostic and management approach when a

child presents with a battery ingestion. This could be done by giving more attention to this subject in medical school, post-graduate pediatric, emergency and family medicine training. In addition, BB flyers in local languages can be prepared by experts and distributed to the professionals, educators, parents, etc. As ESPGHAN task force for battery ingestions we aim at contributing to all these factors, which are paramount for the prevention of BB ingestion. As first steps the task force will aim to organize symposiums during several (medical) conferences, set up a European registry collecting data on BB ingestions and set up media campaigns throughout Europe.

Conclusions and recommendations

On the basis of the available data, the ESPGHAN task force for BB ingestions concludes that:

- Presence of a BB in the esophagus is considered to be a medical emergency and endoscopic removal is necessary as soon as possible (<2 hours).
- Mitigation strategies with honey and sucralfate can be considered in specific cases while waiting for endoscopy, but should not delay it.
- Imaging (CT scan) is important to uncover vascular injury and should be performed in case of delayed (>12 hours after ingestion) diagnosis/ removal (prior to removal) or if severe mucosal damage is seen during endoscopy.
- Removal of gastric BB is necessary in symptomatic cases, in case of co-ingestion with a magnet or in delayed diagnosis.

The ESPGHAN task force for BB ingestions recommends further research on:

- Avoidance of the risk of mucosal injury in case of a battery ingestion e.g. changes in battery design and technology.
- Immediate ingestion of mitigating substances such as honey.
- Efficacy of prevention strategies.
- Follow-up after battery ingestion.
- Evaluating current guidelines in clinical practise.

Summary

Children with BB ingestion commonly present in the emergency department. Such cases are considered highly emergent as mucosal damage can occur within 2 hours if the battery is impacted in the esophagus necessitating urgent endoscopic removal. Children may, however, present with non-specific respiratory or gastro-intestinal symptoms where the ingestion has not been witnessed. Therefore, including battery ingestions in the differential diagnosis of unexplained symptoms is paramount to avoid delaying the diagnosis and increasing the risk of severe complications and even death. The first step after suspected battery ingestion is to stabilize the patient and to perform X-ray studies to localize the battery. If still present in the esophagus or located in the stomach in a symptomatic patient, immediate endoscopic removal is necessary. When located in the airway or above the clavicles, the ENT doctor should be consulted. In asymptomatic cases with location of the battery in the stomach or in the small intestine or colon, patients can be follow-up with X-ray 7-14 days after ingestion. It is important to keep in mind that delayed diagnosis or removal may be associated with more

life-threatening complications. In these cases it is necessary to perform additional imaging (CT scan with contrast) and to consult the surgeon before endoscopy. When a battery is removed, it is also important to follow-up the patient for the development of complications such as esophageal strictures.

Finally, it is of great importance to develop different prevention strategies along with the industry and regulatory agencies. The ESPGHAN task force for BB ingestions aims at playing an important and ongoing role in these prevention plans.

ESPGHAN DISCLAIMER

“ESPGHAN is not responsible for the practices of physicians and provides guidelines and position papers as indicators

References

1. Litovitz T, Whitaker N, Clark L, et al. Emerging battery-ingestion hazard: clinical implications. *Pediatrics* 2010;125:1168-77.
2. Jatana K, Litovitz T, Reilly J, et al. Pediatric button battery injuries: 2013 task force update. *Int J Pediatr Otorhinolaryngol* 2013; 77:1392-1399.
3. Varga Á, Kovács T, Saxena AK¹. Analysis of complications after button battery ingestion in children. *Pediatr Emerg Care* 2018;34:443-6.
4. Eliason M, Ricca R, Gallaghe T. Button battery ingestion in children. *Curr Opin Otolaryngol Head Neck Surg* 2017;25:520-526.
5. Ibrahim A, Andijani A, Abdulshakour M, et al. What Do Saudi Children Ingest?: A 10-Year Retrospective Analysis of Ingested Foreign bodies from a Tertiary Care Center. *Pediatr Emerg Care* 2019;71:443-448.
6. Khorana J, Tantivit Y, Phiuphong C, et al. Foreign body ingestion in pediatrics: Distribution, Management and Complications. *Medicina (Kaunas)* 2019;14;55.
7. Diaconescu S, Gimiga N, Sarbu I, et al. Foreign bodies ingestion in children: experience of 61 cases in a pediatric gastroenterology unit from Romania. *Gastroenterol Res Pract* 2016; 2016:1982567. Epub 2016 Feb 1.
8. Kramer RE, Lerner DG, Lin T, et al. North American Society for Pediatric Gastroenterology, Hepatology, and Nutrition Endoscopy Committee. Management of ingested foreign bodies in children: a clinical report of the NASPGHAN Endoscopy Committee. *J Pediatr Gastroenterol Nutr* 2015;60:562-574.
9. Jatana K, Rhoades K, Milkovich et al. Basic mechanism of button battery ingestion injuries and novel mitigation strategies after diagnosis and removal. *Laryngoscope* 2017;127:1276-82.

10. Yoshikawa T, Asai S, Takekawa Y. Experimental investigation of battery-induced esophageal burn injury in rabbits. *Crit Care Med* 1997;25:2039-44.
11. Tanaka J, Yamashita M, Yamashita M, et al. Esophageal electrochemical burns due to button type lithium batteries in dogs. *Vet Hum Toxicol* 1998;40:193-196.
12. Litovitz T, Whitaker N, Clark L. Preventing battery ingestions: an analysis of 8648 cases. *Pediatrics* 2010;1178-1183.
13. Krom H, Visser M, Hulst J et al. Serious complications after button battery ingestion in children. *Eur J Ped* 2018;177:1063-70.
14. Eliason M, Melzer J, Winters J et al. Identifying predictive factors for long-term complications following button battery impactions: A case series and literature review. *Int J Pediatr Otorhinolaryngol* 2016;87:198-202.
15. Leinwand K, Brumbaugh D, Kramer R. Button battery ingestion in children: A paradigm for management of severe pediatric foreign body ingestions. *Gastrointest Endosc Clin N Am* 2016;26:99-118.
16. Dörterler M. Clinical profile and outcome of esophageal button battery Ingestion in children: an 8-Year retrospective case series. *Emerg Med Int* 2019;3752645.
17. Tan A, Wolfram S, Birmingham M, et al. Neck pain and stiffness in a toddler with history of button battery ingestion. *J Emerg Med* 2011;41:157-160.
18. Tringali A, Thomson M, Dumonceau JM, et al. Pediatric gastrointestinal endoscopy: European Society of Gastrointestinal Endoscopy (ESGE) and European Society for Paediatric Gastroenterology Hepatology and Nutrition (ESPGHAN) Guideline Executive summary. *Endoscopy* 2017;49:83-91.
19. Krom H, Elshout G, Hellingman CA, et al. Foreign body ingestion in children. *Ned Tijdschr Geneeskd.* 2019;163:D4281.
20. National Capital Poison Center. Button battery ingestion triage and treatment guideline. <https://www.poisson.org/battery/guideline>, Accessed date: 23 November 2019.
21. Buttazzoni E, Gregori D, Paoli B, et al. Symptoms associated with button batteries injuries in children: an epidemiological review. *Int J Pediatr Otorhinolaryngol* 2015;79:2200-7.
22. Whelan R, Shaffer A, Dohar J. Button battery versus stacked coin ingestion: A conundrum for radiographic diagnosis. *Int J Pediatr Otorhinolaryngol* 2019;126:109627.
23. Litovitz T. Battery Ingestions: product Accessibility and Clinical Course. *Pediatrics* 1985;75:469-476.
24. Lee J, Lee J, Shim J, et al. Foreign Body Ingestion in Children: Should Button Batteries in the Stomach Be Urgently Removed? *Pediatr Gastroenterol Hepatol Nutr* 2016;19:20-8.
25. Rios G, Rodriguez L, Lucero Y, et al. Endoscopic Findings Associated With Button Battery Ingestion in Children: Do We Need to Change the Protocol for Managing Gastric Location? *Pediatr Emerg Care* 2018. Online ahead of print.

26. Honda S, Shinkai M, Usui Y, et al. Severe gastric damage caused by button battery ingestion in a 3-month-old infant. *J Pediatr Surg* 2010;45:e23-6.
27. Takagaki K, Perito E, Jose F, et al. Gastric mucosal damage from ingestion of 3 button cell batteries. *J Pediatr Gastroenterol Nutr* 2011;53:222-3.
28. Khalaf R, Ruan W, Orkin S et al. Gastric injury secondary to button battery ingestions: a retrospective multicenter review. *Gastrointestinal endoscopy* 2020;92(2):276-283. Epub 2020 Apr 22.
29. Lerner D, Brumbaugh D, Lightdale J. Mitigating risk of swallowed button batteries: new strategies before and after removal. *J Pediatr Gastroenterol Nutr.* 2020;70:542-546.
30. Anfang R, Jatana K, Linn R, et al. pH-neutralizing esophageal irrigations as a novel mitigation strategy for button battery injury. *Laryngoscope* 2019;129:49-57.
31. Soto P, Reid N, Litovitz T. Time to perforation for button batteries lodged in the esophagus. *Am J Emerg Med* 2019;37:805-9.
32. Jatana K, Rhoades K, Milkovich S, et al. Basic mechanism of button battery ingestion injuries and novel mitigation strategies after diagnosis and removal. *Laryngoscope* 2017;127:1276–82.
33. Hoagland M, Ing R, Jatana K, et al. Anesthetic implications of the new guidelines for button battery ingestion in children. *Anesth Analg* 2020;130:665-72.
34. Jatana K, Barron C, Jacobs N. Initial clinical application of tissue pH neutralization after esophageal button battery removal in children. *Laryngoscope* 2019;129:1772-6.
35. Ing R, Hoagland M, Mayes L, et al. The anesthetic management of button battery ingestion in children. *Can J Anaesth* 2018;65:309-18.
36. Templeton T, Terry S, Pecorella M, et al. Button battery ingestion: A true surgical and anesthetic emergency. *Anesthesiology* 2020;132:58.
37. Ruhl D, Cable B, Rieth K. Emergent treatment of button batteries in the oesophagus: evolution of management and need for close second look esophagoscopy. *Ann Otol Rhinol Laryngol* 2014;123:206.
38. Lahmar J, Célérier C, Garabédian E, et al. Esophageal lesions following button-battery ingestion in children: Analysis of causes and proposals for preventive measures. *Eur Ann Otorhinolaryngol Head Neck Dis* 2018;135:91-4.
39. Jatana K, Chao S, Jacobs I, et al. Button Battery Safety: Industry and Academic Partnerships to Drive Change. *Otolaryngol Clin North Am* 2019;52:149-61.
40. <https://www.duracell.com/en-us/press/duracell-debuts-breakthrough-child-safety-feature-lithium-coin-batteries/>
41. <https://www.productsafety.gov.au/system/files/National%20strategy%20for%20improving%20the%20safety%20of%20button%20battery%20consumer%20products.pdf>
42. Fuentes S, Cano I, Benavent M, et al. Severe esophageal injuries caused by accidental button battery ingestion in children. *J Emerg Trauma Shock.* 2014;7:361-21.

Figure 1: Sites of esophageal button battery impaction and related risk of injury
 Adapted by Leinwand et al, 2016.¹⁵ (permission has been obtained)

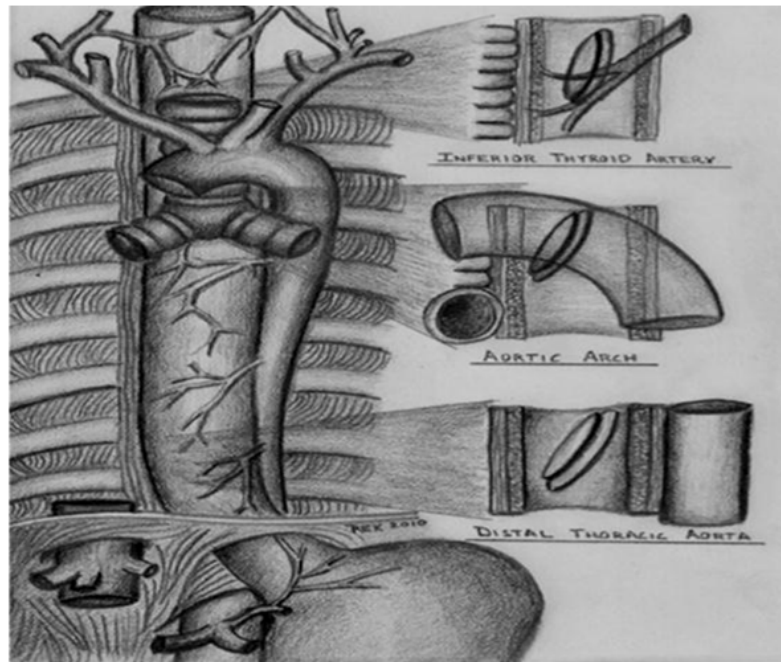


Figure 2: diagnostic algorithm for button battery ingestions

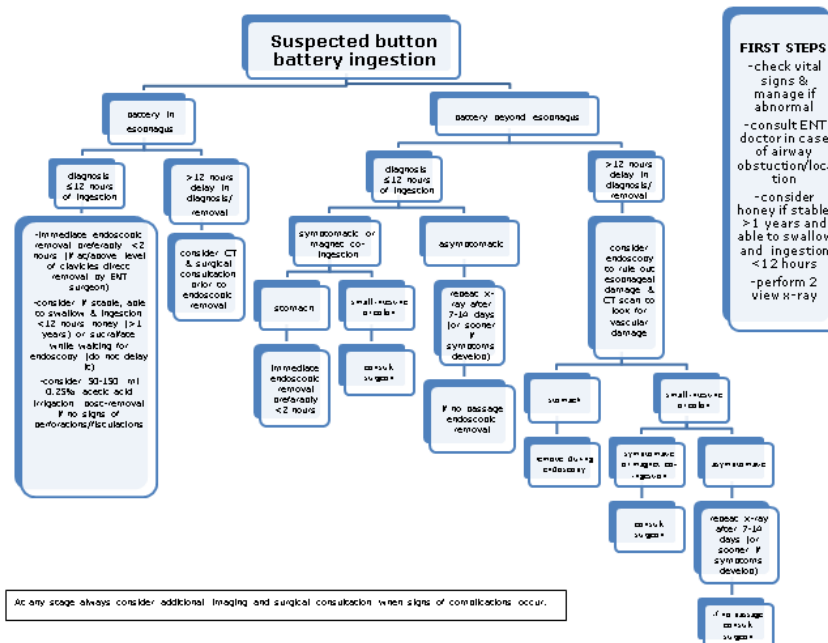


Figure 3: halo sign

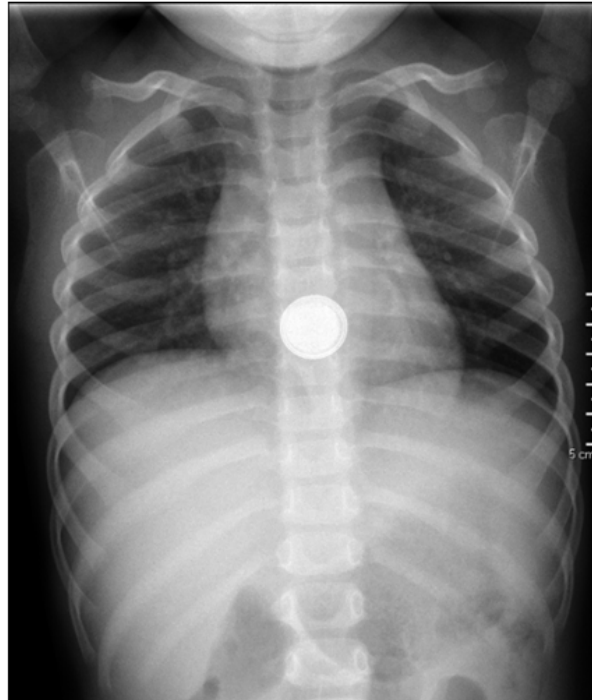

Table 1: button battery complications

Respiratory tract	Gastro-intestinal tract
<ul style="list-style-type: none"> • Nasal septal perforation • Intra-nasal synechiae • Tympanic membrane perforation • Facial nerve paralysis • Recurrent laryngeal nerve injury • Thyroid hemorrhage • Tracheo-esophageal fistula • Battery aspiration • Pulmonary hemorrhage • Bronchial stenosis • Pneumonia 	<ul style="list-style-type: none"> • Esophageal perforation • Esophageal stenosis • Stomach perforation • Small intestine perforation
	<p>Other</p> <ul style="list-style-type: none"> • Aorto-esophageal or other major arterial branch fistula • Massive hemorrhage • Mediastinitis • Spondylodiscitis • Peri-orbital cellulitis